

DEPARTMENT OF ESSENTIAL TRAINING IN
CLINICAL MEDICINE DIAGNOSTICS
Medical University of Lodz

GUIDE to

**THE PRACTICAL COURSE IN
CLINICAL MEDICINE**

Edited by
Władysław Grabski and Dariusz Nowak

Department of Clinical and Experimental Physiology

**Faculty of Biomedical Sciences
and Postgraduate Training,**

Department of Nursing and Obstetrics

Łódź 2009

**Translation consultant – Dr Elżbieta Magdalena Plewińska M.D., Ph.D.
Foreign Language Teaching Centre, Medical University of Lodz**

Dear Students

After long discussions with academic teachers of numerous clinical subjects in our University, we have prepared a program of teaching practical clinical skills to medical students. Acquiring the basics of clinical knowledge by the students before beginning the training with patients is expected to result in the student's more confident attitude to classes at a patient's bed. The classes would also be less stressful for the patient.

In the didactic process, we will use excellent quality phantoms, which are designed for developing practical skills in catheterization of the urinary bladder, gynecological examination, breast examination, blood vessel puncturing, and wound suturing, as well as audiovisual aids such as video cameras, movies or computer simulations.

We put a special emphasis on acquiring by the students: a) the basic skills of the physical examination, b) the basic skills in surgery, c) management of life threatening conditions, d) the basics of the ECG.

We also teach rational clinical thinking, that is both a proper analysis of "the case" and abilities that are useful for communicating with the patient.

This manual is designed as a guide to classes, which are conducted by the experienced teachers from the Department of Teaching Basic Skills in Clinical Medicine, Medical University of Łódź.

Welcome to the Course!

Władysław Grabski, Dariusz Nowak

The Contents

1. Communication skills Tadeusz Pietras MD, PhD

2. The essentials of physical examination:
 medical interview
 physical examination
 prof. Władysław Grabski MD, PhD
 a) Practical guide to chest exam
 Izabela Grabska MD, PhD
 b) Practical guide to abdomen examination
 Małgorzata Saryusz-Wolska MD, PhD

3. Clinical reasoning – quality and quantification
 Piotr Białasiewicz MD, PhD

4. Electrocardiography and the basic analysis
 Krzysztof Chiżyński MD, PhD,
 Sławomir Ceranka MD, PhD,
 Janusz Kawiński MD, PhD

5. The procedures at the site of road accident
 Maciej Morawski MD, PhD

6. The assessment of essential vital signs
 Jan Ruxer MD, PhD

7. The essential resuscitation in adults
 Paweł Kolasiński MD, PhD

8. Desmurgy – imposition of uni-, bi- and triaxial swatches
 Jolanta Glińska MD, PhD

9. Procedures of the intravenous cannula insertion

Maciej Morawski MD, PhD

10. Wound suturing

Wojciech R. Kuzański MD, PhD

11. Breast examination

Włodzimierz Cieśla MD, PhD

12. Principles of catheterization – catheter types

prof. Waldemar Różański MD, PhD

13. Gynecological examination

Włodzimierz Cieśla MD, PhD

14. Ophthalmoscopy

Agata Wesołek-Czernik MD, PhD

Hanna Grymin MD, PhD

15. Otolaryngological examination

prof. Bożydar Latkowski MD, PhD

Niebudek-Bogusz MD, PhD

16. Assessment of practical clinical skills

prof. Dariusz Nowak MD, PhD,

prof. Michał Karasek MD, PhD

Marek Kasielski MD, PhD

Communication skills during medical examination

An appropriate contact with the patient requires applying professional knowledge about psychological aspects of interpersonal relations. While examining the patient, most doctors apply just the experience or abilities to establish interpersonal contacts that have been acquired on a social level. This knowledge would definitely be insufficient in unusual and problematic situations. For many years, clinical and social aspects of doctors' psychological education have been neglected. The ability of conversation should be based on appropriate education, not only on personal intuition or own experience.

The relation between the doctor and the patient is appropriate only if it complies with a set of principles in interpersonal contact. These are: *disinterestedness*, *universality*, *functional specificity* and *affective neutralism*. These terms, being derived from social clinical psychology, need some comment.

Disinterestedness is meant as care provided for the patient benefit and well being, without exploit or regard of own interest, which is quite contrary to the common practice in business relations. *Universality* is medical impartiality and objectivity, despite the relations with the patient. Doctor is obliged by the acknowledged verities of medical society and international associations and by the law. In the medical profession scientific knowledge should dominate over subjective world-views, even if it is against doctor's sense of values. *Functional specificity* in contacts between the patient and doctor is a restriction in going into patient's personal feelings, if the medical diagnostic process does not demand it.

Affective neutralism means doctor's emotional distance. It enables to separate proper medical functioning from personal relations, which are not allowed on medical examination (e.g. sexual or business relations). Affective neutralism does not exclude empathy or emotional support or psychotherapy methods. It is rather an ability to be emotionally neutral to continue the diagnostic process properly. Excessive involvement affects clear thinking and making right decisions. It has been claimed in psychology that appropriate emotional stimulation is necessary to perform an intentional action correctly. Excessive involvement is the source of psychological stress, affects thinking and making decisions. Similarly, decreased involvement can impair a proper performance of a task. Doctor's contact with patient is rooted in the cultural habits of their social environment. These patterns should be used cautiously, not to

offend the patient. The crucial rules are politeness and good manners. Remember to introduce yourself and ask for the permission to take history and examine the patient. On the other hand, some rules can often be destructive for the society; therefore doctors should oppose them and promote healthy habits. A couple of negative cultural habits will be demonstrated here. In many societies **racism** is deep-rooted. Discrimination of patients due to their nationality, religion or skin color cannot take place in contacts with the doctor. **Ageism** is an aversion to old or disabled people that is common in many countries, including Poland. An old, sick and neglected person needs more time and care than a young person who is usually an attractive partner of the conversation. The older deserve your care and concern as much as the younger do. Value of the maturity of the society is its attitude to the sick and mentally ill. **Psychiatrism** is an aversion to mentally ill people and is often accompanied by fears connected with myths about people, who are treated by psychiatrists. It is common in Poland that the history of psychiatric treatment is concealed even from doctors; psychologists and psychiatrists are attributed with abnormality. Meanwhile, about 17% of society suffers from and 11% is addicted to alcohol. Including addiction to nicotine that accounts for 50%, psychiatric problems are equally frequent as problems of internal medicine. Ignorance of this problem also concerns doctors and is a negative phenomenon, which affects medical profession and the society. Lack of any determined opposition and condemnation of such an attitude on doctors' side tends to stabilize the negative image of the mentally ill in the society. **Sexism** is widely understood as discrimination or favoritism of a person because of sex. It is generally a negative phenomenon that affects doctor's contact with the patient. It is widely commented by press.

Communication with the patient functions in two information channels: **verbal and non-verbal**.

Non-verbal communication is a common way of conveying information among animals. In humans, about 30% of information is passed in the way of non-verbal communication. Neither the speaker, nor the listener is aware of the information passed non-verbally. The ability of "reading" non-verbal signals is an important one in the everyday life. It is equally useful in performing doctor's job. We will discuss only a couple of problems connected with this way of communication. The channel of non-verbal communication includes: **face expression, way of looking at doctor, gesture and body movement, posture, touch contact, space behavior, clothing and appearance**. Communication functions in four different ways: interpersonal communication of attitudes and emotions, self-presentation,

customs (e.g. greeting), maintaining verbal communication. Non-verbal communication is underestimated and doctor's professional knowledge in this subject is very limited. Those, who are interested in this issue, are asked to read the recommended literature.

About 70% of information is transmitted among people using *verbal communication*, i.e. speech and language. While talking to the patient, doctor uses language and elicits the information about the patient and his ailment. It enables to form *the activating data*, establish a preliminary diagnosis and begin the diagnostic / therapeutic process. The activities mentioned above used to be called *taking history* and *anamnesis*. Polish students and doctors use mainly the scheme of taking history that was proposed by Orłowski. It will not be discussed here in details, as it is presented in internal medicine books. We would like to point to the fact that, quite contrary to the implications from the scheme by Orłowski, the picture of the disease is not formed after the history has been elicited, but still while the history is being taken. Each answer that is given by the patient implies another question, often not complying with the general principles presented in books. Each doctor works out his own way of obtaining the history. Doctor's personality and patient's personality as well as the picture of the disease are the factors that influence the individualization of examination; each medical history is different, unique. From the patient's point of view, correct reasoning is more important than methodological correctness.

We would like to draw your attention to some mistakes, which are made on eliciting history. Either the doctor, or the patient may misunderstand words that are used by both of them. For the patient these are medical terms and for the doctor - expressions may seem slangy or colloquial. Doctor's language should be simple and adequate to patient's education, medical knowledge and language skills. A similar problem is with understanding the semantic meanings of medical terms. For example, the stomach means a precise organ for the doctor, while it may mean any organ of the abdominal cavity for the patient. This kind of the imprecise function of words in colloquial language should always be considered!

Fear and stress that are caused by visiting doctor may influence patient's expressive ability. Fear is predominant feeling among people waiting for an appointment (as a result of cognitive reflection of the situation). Everyone knows problems with expression during a stressful exam. Similarly, a frightened patient may talk incoherently against his intentions. A nice atmosphere and doctor's kindness should reduce patient's stress. What the patient needs is not only friendly attitude, but also specialist knowledge in psychology of interpersonal relations. Reduction of patient's stress before the examination seems the doctor's task.

Informing patient about the diagnosis and recommendations is another important issue. It is patient's right to ask the question: "What is my health problem?" and receive an answer. If patient knows something about his disease, he usually accepts it and integrates with his own health convictions that can sometimes be divergent from medical knowledge. It is different if the diagnosis causes patient's fear or concerns for future. Tradition in Polish medical practice implies that a bad diagnosis, such as cancer should be concealed. Meanwhile, the law and principles of medicine in the Western Europe countries oblige doctor to tell the whole truth about the diagnosis. Telling the sad truth in a possibly non-traumatic way seems most important. Doctors in Poland are not prepared for this kind of conversations.

Practical part

The aim of the class is to watch your own performance of taking history from a patient. The conversation is recorded on a tape using two video cameras. One is directed at the doctor (student), the other one - at the patient. The images of the patient and doctor are presented simultaneously on the screen of the video player.

After taking history it is played back to be analyzed by the student and the whole group. Pay attention to:

- way of introducing yourself and asking for the permission to examine the patient,
- ability to communicate,
- doctor's mimics and non-verbal communication,
- way of eliciting history, accuracy, including:
 - taking personal data,
 - detailed family history,
 - main complaints,
 - the course of the disease,
 - past history,
 - the course of the main ailment,
 - profession,
 - addictions and habits,
- coherence of the asked questions

- creating a preliminary hypothesis

Keep in mind that the vision of you on videotape differs from your own vision of yourself (“real me” differs from “perfect me”); own evaluation is usually decreased.

ESSENTIALS OF EXAMINING THE PATIENT

„A doctor is expected to be able to show his compassion and understanding, since the patient is not a mere sum of symptoms, impaired functions, injured organs and rough emotions – the patient is a human being, who is full of both fear and hope; the one who is looking for relief and support.”

T. R. Harrison

According to the quoted above concept, a student – future doctor, should learn ideas, observations and schemes that have been used in the art of medicine by Polish and foreign masters, i.e. professors: Witold Orłowski, Edward Szczeklik, Jan Tatoń, T. Harrison and W. W. Keen. Their ideas help us determine doctor’s attitude towards the patient and can be achieved by studying the consecutive stages of work with the patient. These are: taking history, physical examination, clinical reasoning, tentative diagnosis, choosing instrumental examinations and accessory laboratory tests, basic diagnosis, differential diagnosis and treatment (Fig. 1). Acquiring all these abilities makes a student turn into a doctor. This textbook as well as the practical course using phantoms will certainly prove helpful in achieving the necessary skills.

The textbook includes the schemes of:

- a) obtaining **history** - when the patient is investigated in a planned, reasonable and not suggestive way

- b) performing **physical examination** – which is also taught at the early stages of medical education, when students learn that physical manifestations are objective and verifiable results of a pathological process.

The scheme of the clinical examination that we present here includes expressions and figures from the publications of the previously mentioned authors.

We use computer simulations to teach students how to take history, and professional phantoms and volunteers (students) – to present the essentials of the physical examination.

The ability of **clinical thinking** is a very important field of knowledge that is taught to students. It usually leads from the syndromes to the signs, through disease complexes to the particular disease.

We believe, that our didactic work in the Institute of Clinical Medicine Education, in cooperation with doctors from the Medical University Clinical Departments will sufficiently prepare the students for the clinical work - at patient's bed. It seems very important that using simulations on phantoms and computer programs during the practical course remarkably spares patients and is consistent with the ethical requirements of the European Union.

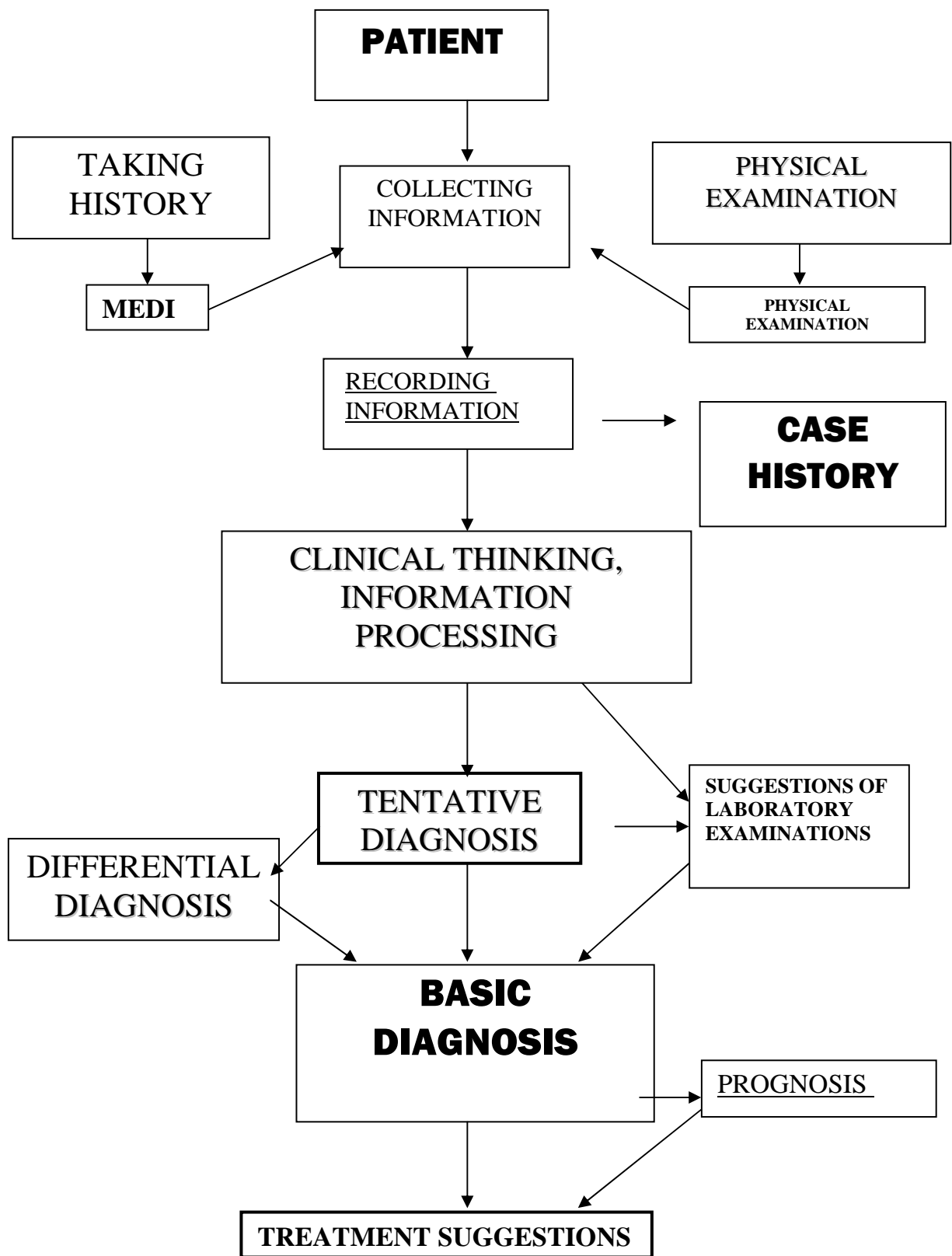


Fig. 1. Approach to the patient

- A. Manifestations that are patient's sensations
 - impossible to verify – **syndromes** (anamnesis)
- B. Physical examination reveals symptoms of the disease
 - **signs** – revealed thanks to appropriate methods of examination (physical examination).

Description of patient's examination – anamnesis + physical examination is called **case history**. It should include every fact of medical significance that has taken place before visiting the doctor.

ref. A. **ANAMNESIS**

Start the examination with coming into contact with the patient.

- Greet the patient – e.g. Good morning, Mr. Kowalski!
- Shake his hand.
- Put your hand on his hand.
- Introduce yourself.
- Ask his name, profession, marital status.

This attitude enables a doctor or a student to establish a proper relation with the patient, which makes further cooperation easier.

Ask the patient about the reason for his visit; what are his complaints?

Let him talk about his complaints using his own words as long as necessary.

Listen carefully and make notes.

Do not demonstrate irritation if the history is unclear or if you think that some information is not important or contributory. If you interrupt too fast, you may miss an important syndrome, if you keep listening you will know which symptoms are important for your patient.

Let the patient talk for about 2 minutes.

Patients talk about their complaints in many ways. Sometimes they do not make any distinction between important and irrelevant symptoms and tend to cover the crucial theme by exposing inessential details.

That is why you should take over the conversation – ask more detailed questions, interrupt patient to avoid too complicated, long stories.

If you think that you obtained the crucial information, stop the conversation politely but firmly. You may also get involved in the statement – follow the story – formulate questions to determine the symptoms and the progress of syndromes that made the patient visit the doctor.

The **disease picture** is thereby formed providing the information about:

- circumstances and sequence of symptom appearance (e.g. dietary indiscretion, cold, fatigue)
- permanency, intensity, frequency and duration of the disease and accompanying symptoms.
- medications used – which (names) and if they brought a relief, the symptoms were passing away (in what situations)

In a disease that starts suddenly, severely e.g. with fever or pain, the patient can point precisely to the onset of the distress and its duration.

In a chronic disease, which starts imperceptibly, the duration is difficult to assess and only combined efforts of both patient and doctor (student) may finally be successful. Determination of the disease duration may immediately suggest the right route to diagnosis.

Sometimes, instead of describing the symptoms the patient informs that he suffers from asthma, angina pectoris or tuberculosis. Then, he should be enquired about the syndromes of the mentioned diseases.

GENERAL COMPLAINTS

Having obtained the history including general complaints, complete it with **general ailments** and **symptoms from the particular organs**. Consider questions referring to their function.

While history taking, the doctor (student), should mention the most common disorders bothering patients, as the patient forgets to tell about them if they do not occur on examination.

GENERAL MALAISE

- if it occurred suddenly
- if it has aggravated gradually (since when)

If the patients suffers from:

HEADACHES – in which area, circumstances, seasons, time of the day, permanent or periodic; if they are accompanied by vision impairment, photophobia, nausea or vomiting.

VERTIGO – accompanying symptoms, circumstances of the onset, permanent or periodic

HOT FLASHES – on the face, head

FEVER – shivers, in the morning, at night

SWEATING – the character: excessive, periodic, permanent

BODY WEIGHT – if he has lost, gained weight – if his stomach girth has enlarged, association with dietary habits

OEDEMA – if it is present, happened before, in which body area and how long it was present

If he complains of:

NOSE BLEEDING occurring suddenly, after exertion, during colds, without apparent reason

If the following symptoms occurred:

DYSPNOEA

- after exertion – what loading
- at rest, permanent, paroxysmal, how often it occurs, how long it lasts
- if paroxysms are associated with the seasons, onset after drugs (names)

COUGH

- since when, frequency,
- on exertion, at rest,
- on changing body position,
- associated with seasons, time of the day
- dry or productive
- bringing up sputum, its color – white, yellow, blood stained, its smell

STABBING PAIN IN CHEST

While breathing deeply or regardless of respiratory movements, pain rapidity, localization, radiation.

HEART BEAT OR PALPITATION

when, - circumstances, reasons e.g. exertion, drinking coffee

- at night,

- with no apparent reason.

HEART STOPPING FEELING

- if occurs, establish the circumstances

SORE THROAT– permanently, sporadically, accompanied by fever, on swallowing- if positive-what kind of food (solid, liquid)

HOARSENESS – how often, related with seasons, drugs

DISTURBED SWALLOWING – if complains of problems with swallowing food, establish the consistency of meals (liquid, solid)

- pain on swallowing,

- vomiting

BAD TASTE IN THE MOUTH

SALIVATION OR XEROSTOMIA – when, in what circumstances

GLOSSOPYROSIS

THIRST

- increased
- disturbed
- normal

APPETITE

- increased
- disturbed
- anorexia
- lack

HEARTBURN in the stomach, esophagus – when fasting, after meal, what kind of meal – name it what quantity

HEAVINESS IN THE EPIGASTRIC FOSSA

- when, what time after meal
- details about meal quality and quantity

If the ailment occurs, characterize it: it's radiation and accompanying symptoms.

NAUSEA, VOMITING

If these are associated with headaches, meals, pregnancy

- what is being vomited

- chyme,
- water,
- coffee-grounds,
- fresh, red blood,
- taste of vomits (sour, bitter)

If vomiting brings relief to the patient or does not influence patient's feeling

Ask about **BOWEL MOVEMENT** frequency – *do not rely on patient's complaint of diarrhea because the patient may not understand the meaning of this word*

- whether there is pain, tenesmus while relieving stool, ask about melaena (coffee dregs)

This symptom is significant only if the patient has not eaten blackberries nor taken certain medications (medicinal charcoal).

- fresh blood in stool should draw doctor's attention
- ask about additional contents in stool: mucus, pus, worms and remains of undigested food.

Disorders in **URINATION**

- frequency, nocturnal urination, burning, urgency, urine flow, urinary incontinence, whites, urethrorrhoea (males)
- Ask about: pain in the lumbar region, if positive- its radiation (to the pubic symphysis, to the urethra) and accompanying symptoms.

Pain may be the result of nephropathy or accompany the lumbar vertebrae dysfunction

Obtain information about **THE MUSCLE AND SKELETAL SYSTEMS**

- ask about pain in the joints, joint rigidity, localization, accompanying symptoms (edema, redness, tenderness),
- muscle pain, muscle rigidity, weakness, tingling sensations

Assess **SKIN** sensations with the patient:

- itching
- rash
- fistulae

Ask about **SLEEP** – difficulties in falling asleep. Ask if he wakes up rested, if he has problems with falling asleep, find the reasons for the abnormalities reported.

On taking history, do not ignore patient's complaints of GENERAL MALAISE, anxiety, apathy, which may be symptomatic of many diseases.

Enquire about VISUAL DISTURBANCES and symptoms including visual acuity, using glasses or contact lenses, eyeball movements, redness, lacrimation, itching, double vision, spots.

Ask about HEARING (AUDITION) tinnitus, otorrhoea.

Ask about disorders of THE REPRODUCTIVE ORGANS.

Men usually complain of impotence and premature ejaculation. Women complain of dysmenorrhoea, whites, pain in the hypogastrium, pruritus of the vulva. Make sure if the periods are regular, when they started (or ended). Whether the periods are regular, how long they last, if they are excessive, painful. Ask about pregnancy, labor, whether the labor was spontaneous or instrumental (caesarean section, forceps) miscarriages.

In the case of patients with numerous incidental sexual intercourses, condom usage should be enquired about, especially in homosexuals (AIDS).

Ask about PAST DISEASES

- a) childhood diseases (measles, pertussis, scarlet fever, mumps, rubella)
- b) adult diseases (tuberculosis, diabetes, typhoid fever, tonsillitis, jaundice), past surgeries

Ask about the HOUSING CONDITIONS - city - country

- if it is dry, sunny or humid and dark, old or new housing estate
- if there are any conveniences, how many members of the household

Ask the patient about stimulants:

- if he **smokes**, how much per day and since when,
- if he **drinks alcohol** and how much,
- ask about **coffee, tea and other stimulants**

Obtain family history; ask about the parents' age and health condition, reason of death if needed. Information concerning the health condition of the siblings, children or even cousins may be contributory.

Ask about the incidence of any diseases in the family: diabetes, heart diseases, hypertension, stroke, nephropathy, tuberculosis, neoplasms, arthritis, allergy, mental diseases, alcoholism, drug addiction and the symptoms present in a given patient.

Ask about patient's **OCCUPATION**

- whether the patient is educated
- jobs performed; kind of work – physical, intellectual
- risk factors associated with patient's job

„There is nothing like a sharp eye, sensitive ear, skillful hand and logical mind, that would make use of all the sources of information, thus leading to the establishment of the precise diagnosis”

W. W. Keen

PHYSICAL EXAMINATION

1. GENERAL APPEARANCE:

Behaviour:

Conscious	<input type="checkbox"/>
Delirious	<input type="checkbox"/>
Excited	<input type="checkbox"/>
Apathetic	<input type="checkbox"/>
Uncommunicative	<input type="checkbox"/>

Facial expression – *observation at rest and during conversation*

Painful	<input type="checkbox"/>
Faint-hearted	<input type="checkbox"/>
Hippocratic face	<input type="checkbox"/>
Normal	<input type="checkbox"/>

Body position

Free	<input type="checkbox"/>
Compulsory	<input type="checkbox"/>

Gait

Balanced	<input type="checkbox"/>
Unsteady	<input type="checkbox"/>
Limping	<input type="checkbox"/>
Falling risk	<input type="checkbox"/>
Abnormal movements	<input type="checkbox"/>

2. VITAL SYMPTOMS

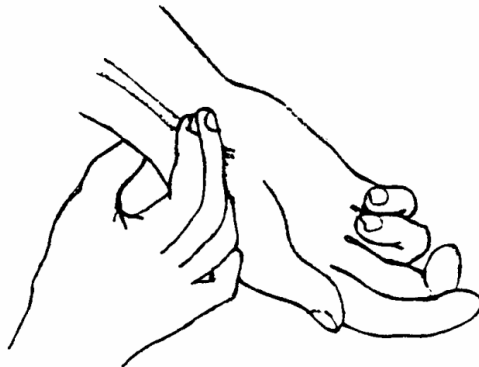

Fig.2. Examination of pulse on radial artery.

Pulse

- Regular
- Irregular
- Symmetric yes no
- Rate
- Filled
- Abrupt
- High
- Tetchy yes no

Respiration:

- Rate per minute
- Regularity

Blood pressure (systolic and diastolic)

Body temperature

- In the armpit
- Rectal

3. HEIGHT, WEIGHT

- Tall cm
- Short cm

Nutrition

Obese

Slim

Emaciated

Body structure:

Leptosomic

Asthenic

Pyknic

Athletic

BODY MASS INDEX BMI = M/H²

M – real body weight [kg]

H – height [m]

normal **F** - 22-25

M -22-26

SKIN EXAMINATION

Colour

Cyanosis

Redness

Xanthosis

Pallor

Browning

Vascularization

Telangiectasias

Petechiae

Cutaneous effusions

Bloodstains

Collateral circulation

Hydratation

Dry
Hydrated

Temperature

Increased
Decreased

Skin surface

Rough
Smooth

Skin elasticity

Tensed
Elastic
Loose
Scars
Infiltration
Birthmarks
Rush
Pilosity
Type F M

Nails

Normal
Convex
Concave
Wrinkled
Agnail

Oedemas

yes no
Generalized
Local
Body regions
Face
Around ankles
Calves
The sacral region

THE HEAD AND NECK

The cranium

Symmetrical	<input type="checkbox"/>
Tower skull	<input type="checkbox"/>
Platycrania	<input type="checkbox"/>
Wide	<input type="checkbox"/>
Tenderness	
palpable	<input type="checkbox"/>
percussion	<input type="checkbox"/>
tumours	<input type="checkbox"/>
scars	<input type="checkbox"/>

The face

Symmetrical	<input type="checkbox"/>
Deformed	<input type="checkbox"/>
Palpable	
trifacial neuralgia	<input type="checkbox"/> yes <input type="checkbox"/> no

The eyes

Palpebral fissurae symmetrical	<input type="checkbox"/> yes <input type="checkbox"/> no
Eyeballs setting	
Normal	<input type="checkbox"/>
Exophthalmos	<input type="checkbox"/>
Mobile	<input type="checkbox"/> yes <input type="checkbox"/> no
Grafe's sign	<input type="checkbox"/>
Mobius' sign	<input type="checkbox"/>
Stellwag's sign	<input type="checkbox"/>

The pupil

Wide	<input type="checkbox"/>
Narrow	<input type="checkbox"/>
Deformed	<input type="checkbox"/> yes <input type="checkbox"/> no
Reaction to:	
light	<input type="checkbox"/> yes <input type="checkbox"/> no

convergence yes no

fixation yes no

The ears

External ear

Auricles

Symmetrical yes no

Palpable tenderness
of the mastoid process yes no

Otorrhoea

present

not observed

The nose

Symmetrical yes no

Patent yes no

Discharge, if present:

purulent

mucous

The oral cavity and the pharynx

The lips

Symmetrical yes no

Dry

Moist

Herpes yes no

The oral mucosa

Moist

Dry

Glossy

Mat

Pale

Pink

Ulceration yes no

Thrush yes no

Petachiae yes no

Dentition

Full

Declines

Caries

Prosthetic restoration

Dentures

The tongue

Symmetrical yes no

Deviation while sticking out yes no

Moist

Dry

Coated yes no

Smooth yes no

Chapped yes no

Ulceration yes no

Thrush yes no

Palatine tonsils

Present yes no

Enlarged yes no

Coated yes no

Ulceration yes no

The parotid gland

Enlarged yes no

Palpable tenderness yes no

THE NECK

(inspection, palpation)

Long		<input type="checkbox"/>
Short		<input type="checkbox"/>
Normal mobility	<input type="checkbox"/> yes	<input type="checkbox"/> no
Skin		
scars	<input type="checkbox"/> yes	<input type="checkbox"/> no
ulceration	<input type="checkbox"/> yes	<input type="checkbox"/> no
Enlarged thyroid gland	<input type="checkbox"/> yes	<input type="checkbox"/> no
Jugular veins		
filled		<input type="checkbox"/>
collapsed		<input type="checkbox"/>

Examination of the thyroid gland




Fig.3. Examination of the thyroid gland – palpation

a – the doctor is standing behind the patient, who is sitting

b – the doctor is in front of the patient; his right hand is palpating the left lobe, his left hand is resting on the neck and his fingers are stabilizing the lobe

Enlarged	<input type="checkbox"/> yes	<input type="checkbox"/> no
Symmetrical	<input type="checkbox"/> yes	<input type="checkbox"/> no

Consistency

rigid

soft

Murmurs over the thyroid gland

 yes no

EXAMINATION OF THE SUPERFICIAL LYMPH NODES

– *If they are enlarged (palpable)*

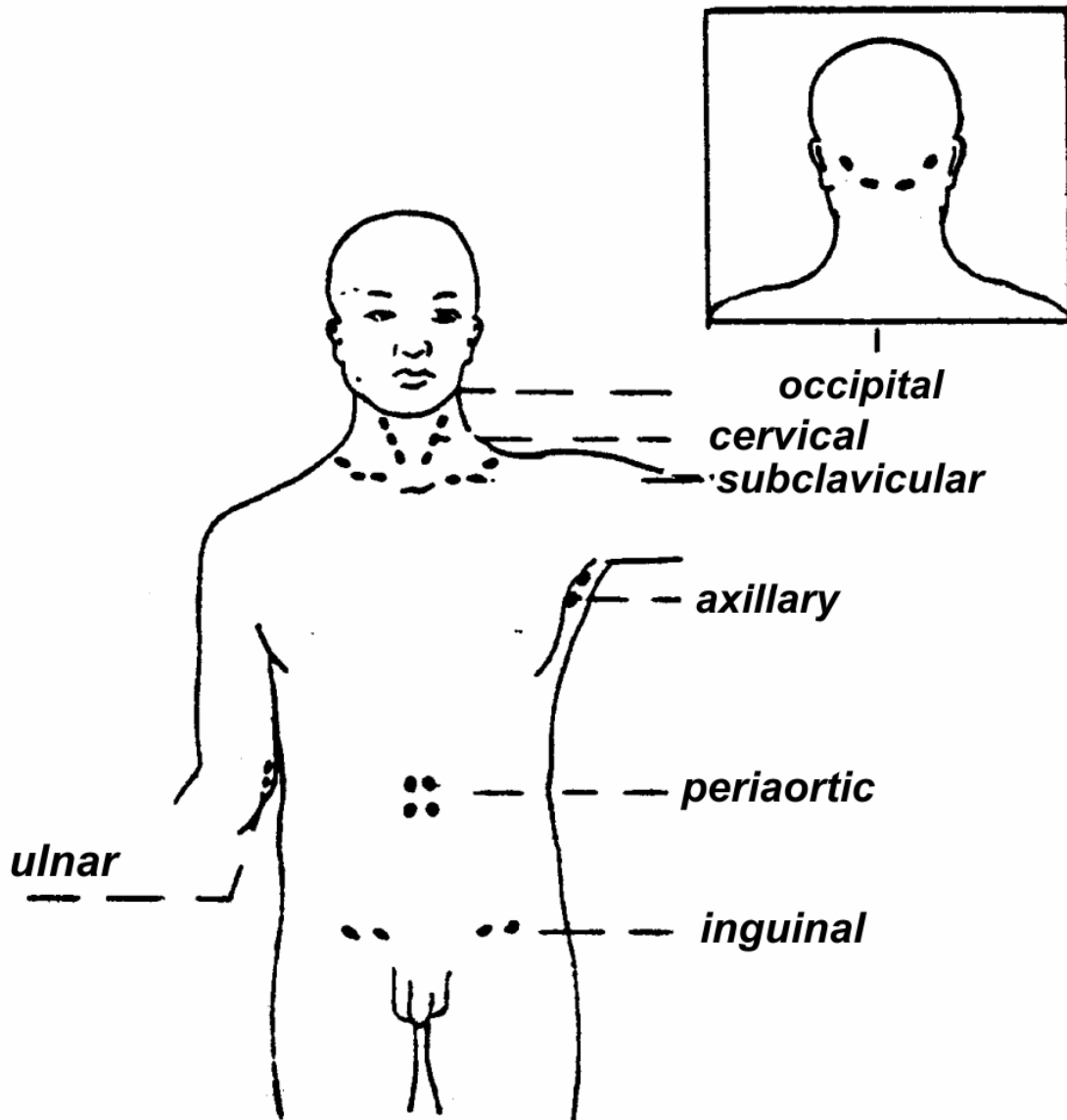


Fig.4. Lymph nodes

Occipital	<input type="checkbox"/> yes	<input type="checkbox"/> no
Cervical	<input type="checkbox"/> yes	<input type="checkbox"/> no
Subclavicular	<input type="checkbox"/> yes	<input type="checkbox"/> no
Axillary anterior	<input type="checkbox"/> yes	<input type="checkbox"/> no
median	<input type="checkbox"/> yes	<input type="checkbox"/> no
posterior	<input type="checkbox"/> yes	<input type="checkbox"/> no
Inguinal	<input type="checkbox"/> yes	<input type="checkbox"/> no
Ulnar	<input type="checkbox"/> yes	<input type="checkbox"/> no

Look at the figure, asses the size, answer the questions:

Are they tense?	<input type="checkbox"/> yes	<input type="checkbox"/> no
Are they mobile?	<input type="checkbox"/> yes	<input type="checkbox"/> no
Are they tender on palpation?	<input type="checkbox"/> yes	<input type="checkbox"/> no

EXAMINATION OF THE THORAX

(inspection, palpation, percussion, auscultation)

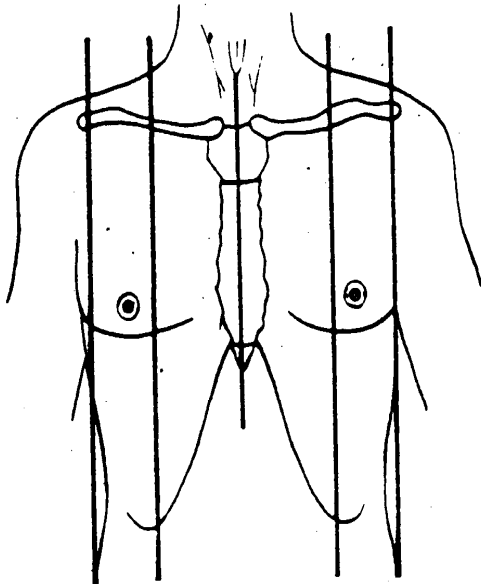


Fig.5. Topographic lines on the anterior wall of the thorax. From left: right anterior axillary line, right midclavicular line, sternal line (median), left midclavicular line, left anterior axillary line

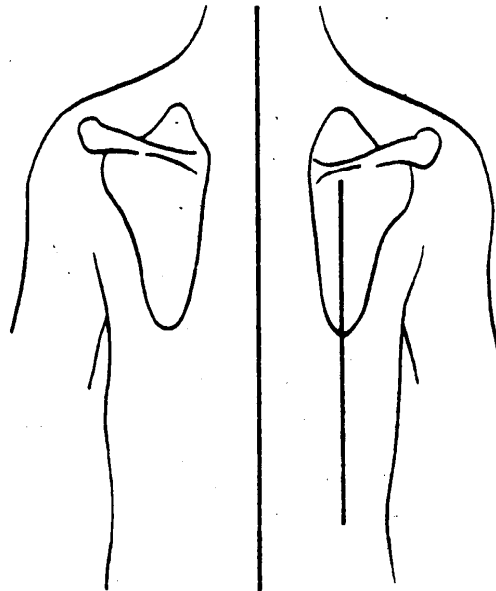


Fig.6. Topographic lines on the posterior wall of the thorax. Vertebral and scapular lines are marked.

Shape

Symmetrical	<input type="checkbox"/> yes	<input type="checkbox"/> no
Bulgy		<input type="checkbox"/>
Shallow (flat)		<input type="checkbox"/>
Asthenic		<input type="checkbox"/>
Piriform		<input type="checkbox"/>
Cobbler's chest		<input type="checkbox"/>
Pigeon chest		<input type="checkbox"/>

Deformations

Inborn		<input type="checkbox"/>
Acquired		<input type="checkbox"/>
Scoliosis		<input type="checkbox"/>
Lordosis		<input type="checkbox"/>
Kyphosis		<input type="checkbox"/>

Mobility

Respiration rate per minute		<input type="checkbox"/>
Respiration		
Abdominal		<input type="checkbox"/>
Thoracic		<input type="checkbox"/>

Pulsations	<input type="checkbox"/> yes	<input type="checkbox"/> no
Tumors	<input type="checkbox"/> yes	<input type="checkbox"/> no
Rib pain	<input type="checkbox"/> yes	<input type="checkbox"/> no

RESPIRATORY SYSTEM EXAMINATION

(Inspection)

Respiratory movements

Abdominal		<input type="checkbox"/>
Thoracic		<input type="checkbox"/>
Mixed		<input type="checkbox"/>
Paradoxical movements of the diaphragm	<input type="checkbox"/> yes	<input type="checkbox"/> no
Symmetry of respiratory movements	<input type="checkbox"/> yes	<input type="checkbox"/> no
Intercostal retraction	<input type="checkbox"/> yes	<input type="checkbox"/> no

Intercostal bulging	<input type="checkbox"/> yes	<input type="checkbox"/> no
Activity of the accessory muscles	<input type="checkbox"/> yes	<input type="checkbox"/> no

(Chest palpation)

Pectoral fremitus

Present	<input type="checkbox"/>
Absent	<input type="checkbox"/>
Symmetrical	<input type="checkbox"/>
Asymmetrical	<input type="checkbox"/>

Pleural friction rub

<input type="checkbox"/> yes	<input type="checkbox"/> no
------------------------------	-----------------------------

(Percussion)

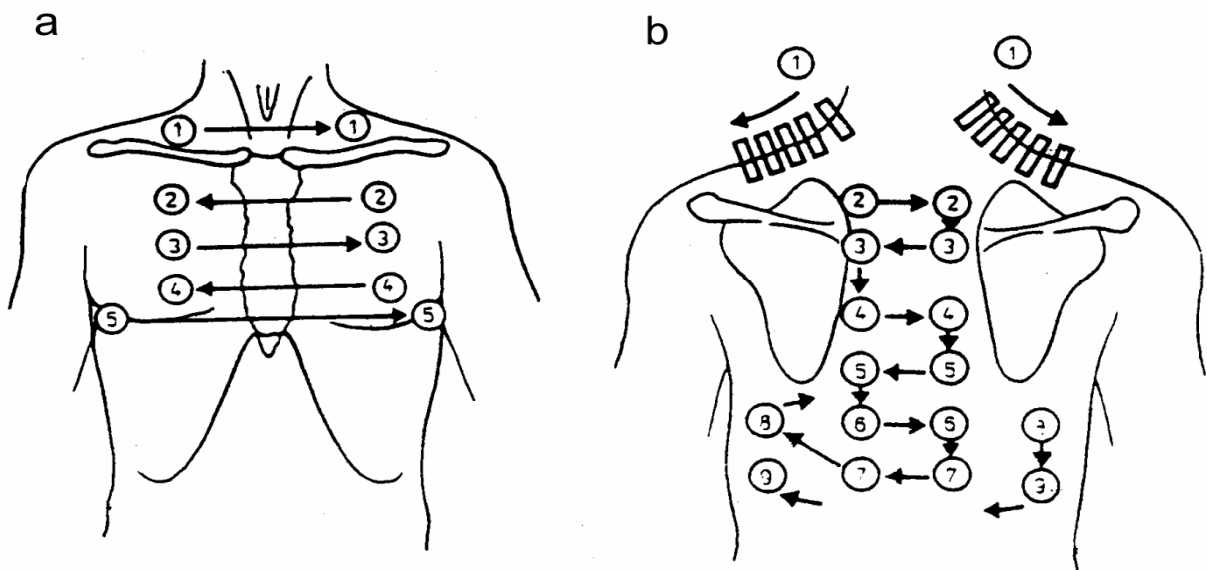


Fig.7. Places of percussion and auscultation: a – front, b – back
The numbers show the order of the examination

Percussion sound in typical places:

(centres of the supraclavicular fossae, middle parts of the second intercostal spaces anteriorly, in the fourth intercostal spaces laterally to the midclavicular lines, on both sides in the sixth intercostal spaces in the midaxillary lines, the middle of supraspinous regions, in the middle of the right and left interscapular area, the interscapular line – 2 cm below the angle of the scapula.)

Percussion sound

Vesicular	<input type="checkbox"/> yes	<input type="checkbox"/> no
Tympanic resonance	<input type="checkbox"/> yes	<input type="checkbox"/> no
Dull	<input type="checkbox"/> yes	<input type="checkbox"/> no
Mobility of the lower lung lines	<input type="checkbox"/> yes	<input type="checkbox"/> no

(Auscultation)

Basic respiratory murmurs

Vesicular	<input type="checkbox"/> yes	<input type="checkbox"/> no
Normal	<input type="checkbox"/> yes	<input type="checkbox"/> no
With prolonged inspiration phase	<input type="checkbox"/> yes	<input type="checkbox"/> no
Exacerbated	<input type="checkbox"/> yes	<input type="checkbox"/> no
Bronchial	<input type="checkbox"/> yes	<input type="checkbox"/> no

Accessory murmurs

Dry rales	<input type="checkbox"/> yes	<input type="checkbox"/> no
Wheezes	<input type="checkbox"/> yes	<input type="checkbox"/> no
Whirring rales	<input type="checkbox"/> yes	<input type="checkbox"/> no
Moist rales	<input type="checkbox"/> yes	<input type="checkbox"/> no
Resonant		<input type="checkbox"/>
Dull		<input type="checkbox"/>

Pleural friction rub murmur	<input type="checkbox"/> yes	<input type="checkbox"/> no
------------------------------------	------------------------------	-----------------------------

EXAMINATION OF THE MAMMARY GLAND

Female mammary gland examination

Symmetrical		<input type="checkbox"/>
Asymmetrical		<input type="checkbox"/>
Flattening observable	<input type="checkbox"/> yes	<input type="checkbox"/> no
Depressions observable	<input type="checkbox"/> yes	<input type="checkbox"/> no

Skin appearance

Oedematous	<input type="checkbox"/> yes	<input type="checkbox"/> no
		<input type="checkbox"/>

Orange skin	<input type="checkbox"/> yes	<input type="checkbox"/> no
Ulceration	<input type="checkbox"/> yes	<input type="checkbox"/> no

Nipples

Prominent	<input type="checkbox"/>	<input type="checkbox"/>
Pulled into	<input type="checkbox"/>	<input type="checkbox"/>
Tenderness on palpation	<input type="checkbox"/> yes	<input type="checkbox"/> no
Palpable tumours	<input type="checkbox"/> yes	<input type="checkbox"/> no

Mark points in the figure

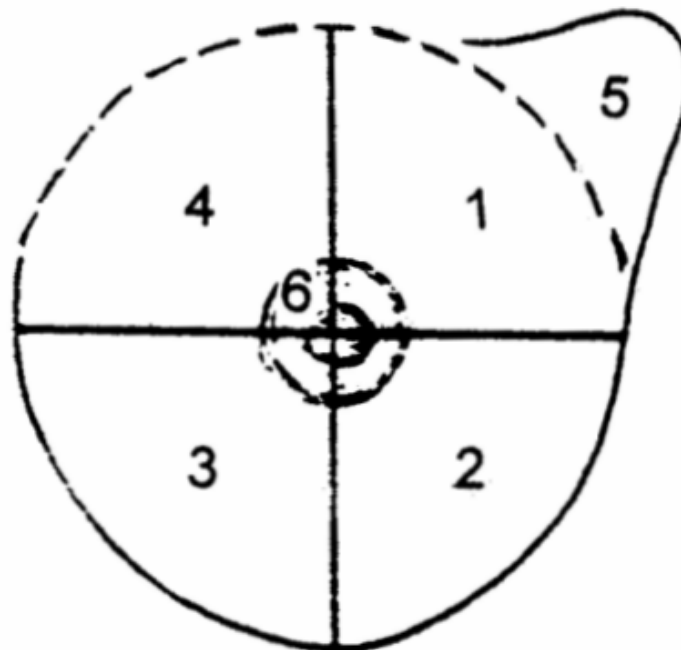


Fig.8. Topographic regions of the breast – left mammary gland

- 1 – upper lateral quadrant, 2 – lower lateral quadrant,
- 3 – lower medial quadrant, 4 – upper medial quadrant,
- 5 – axillary tail of the breast, 6 – nipple area, central portion of the breast

Nodules - if present, pay attention to

- location,
- size
- shape
- consistency
- tenderness
- mobility

If exerting pressure on the breast causes leakage

yes

no

Male mammary glands

Symmetrical

yes

no

Enlarged

yes

no

Enlarged nipples

yes

no

HEART

(Inspection)

The area of the heart

Prominent

Normal

Apex beat

Visible

Invisible

Parasternal raising

yes

no

Dynamic aorta

Visible

Invisible

(Palpation)

Apex beat

Palpable

Covered with the pulp of 1,2,3....fingers

yes

no

Impalpable

Heart area tremor

Palpable

Impalpable

(Percussion) **Heart lines**

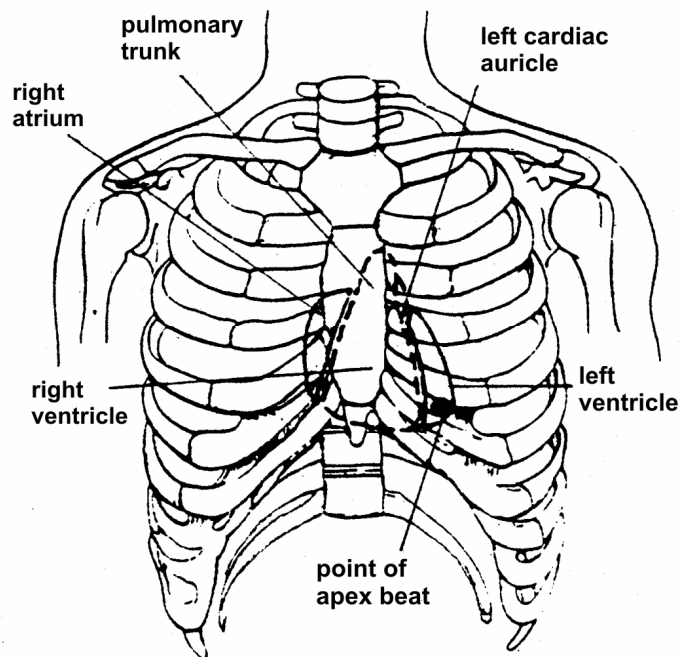


Fig.9. Projection of the heart on the anterior wall of chest:
the trunk of the pulmonary artery, the right atrium, the right ventricle, the left ventricle,
the left cardiac auricle and the point of apex beat.

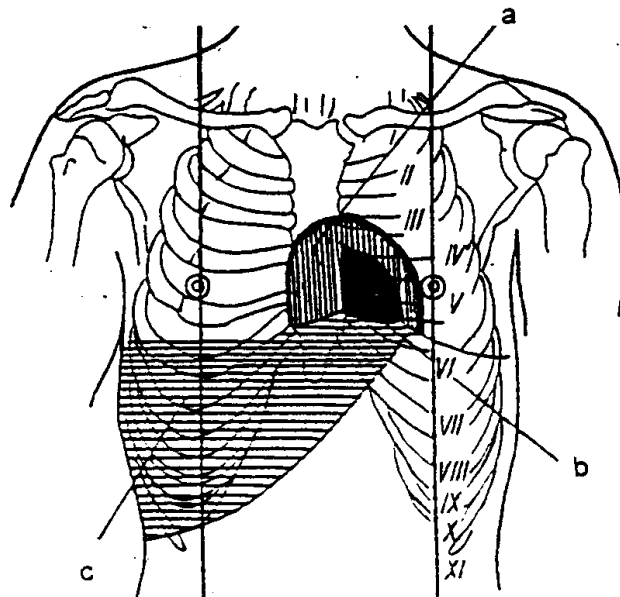


Fig.10. The heart dullness:
a – relative, b – absolute, c – hepatic dullness

	ABSOLUTE DULLNESS (SMALL)	RELATIVE DULLNESS (BIG)
UPPER LINE	in the left sternal line – the upper edge of the fourth rib	the third intercostal space in the parasternal line
RIGHT LINE	along the left sternal line	along the right sternal line
LEFT LINE	1 cm medially to the left midclavicular line	1 cm medially to the left midclavicular line

Auscultation

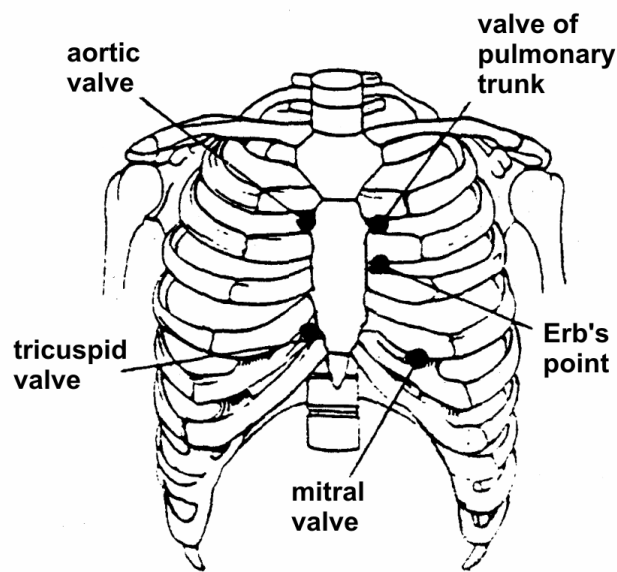


Fig.11. Typical points of heart auscultation

Heart beat

- Regular
- Irregular
- Rate per minute

Heart sounds

- Loud yes no
- Dull yes no

Sounds:

Sound 1

Sound 2

Sound 3

Sound 4

Intervals between the sounds yes no

Murmurs yes no

Systolic

Diastolic

Pericardial friction rub yes no

EXAMINATION OF THE ARTERIES

(Inspection, palpation, auscultation)

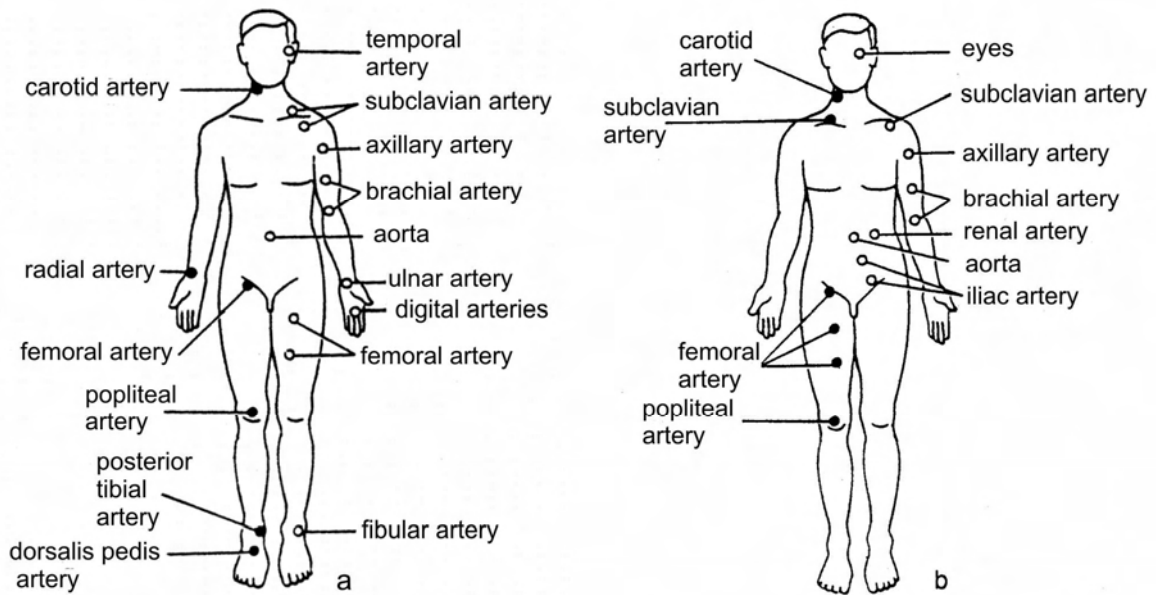


Fig.12. Arteries available on palpation (a) and auscultation (b)

(The aorta, the carotid arteries, the radial arteries, the ulnar arteries, the superficial femoral arteries, the popliteal arteries, the tibial arteries, the dorsal foot arteries are partially available on palpation.)

Pulsation of arteries

Visible

Invisible

(Palpation) Arteries

The wall of the artery

rectilinear

serpentine

fine

hardened

elastic

rigid

Pulse palpable yes no

Equal on both

symmetrical arteries yes no

(Auscultation)

the carotid artery , the thyroid gland level

murmurs yes no

the subclavian artery, below the middle of the clavicle

murmurs yes no

the renal arteries, the epigastrium and lumbar region

murmurs yes no

VEINS

(Inspection, palpation)

Jugular veins

Filled yes no

Collapsed yes no

Venous pulse positive

Venous pulse negative

Veins of the lower limbs

Clots yes no

THE ABDOMINAL CAVITY

(examined in patient supine position or upright and bending over)

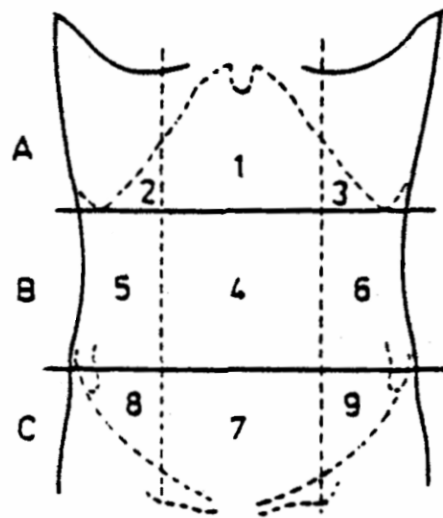


Fig.13. Topography of the anterior abdominal wall
 1 – the epigastric area 2 – the right subcostal area,
 3 – the left subcostal area, 4 – the umbilical area,
 5,6 – the abdominal lateral area, 7 –the pubic area,
 8, 9 – the inguinal area

(Inspection)

The symmetry of the abdomen	<input type="checkbox"/> yes	<input type="checkbox"/> no
The shape of the abdomen		
Protuberating		
in the level of the thorax		<input type="checkbox"/>
above the level of the thorax		<input type="checkbox"/>
lower than the level of the thorax		<input type="checkbox"/>
The umbilicus		
Protruding		<input type="checkbox"/>
Pulled into		<input type="checkbox"/>
Signs of umbilical inflammation		<input type="checkbox"/>
Umbilical hernia		<input type="checkbox"/>
The peristalsis – visible	<input type="checkbox"/> yes	<input type="checkbox"/> no
Pulsation in epigastrium	<input type="checkbox"/> yes	<input type="checkbox"/> no

(Palpation) general

Integument tension

increased

normal

pain on palpation yes no

local pain yes no

diffuse pain yes no

Blumberg sign

positive

negative

(Palpation) detailed

The liver

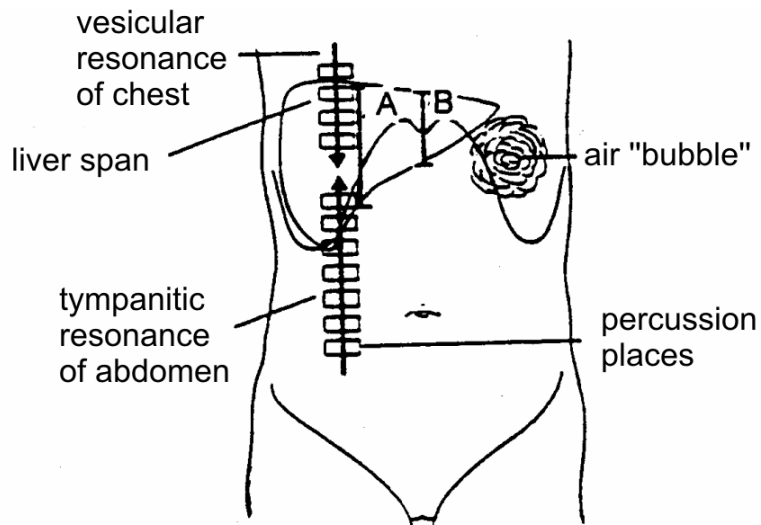


Fig.14. Liver percussion – anteriorly:

A – the width of dullness in the midclavicular line = 6-12 cm

B – the width of dullness in the medial body line = 4-8 cm

Enlarged yes no

Consistency:

hard

soft

Liver edge		
acute		<input type="checkbox"/>
blunt		<input type="checkbox"/>
Surface		
smooth		<input type="checkbox"/>
nodular		<input type="checkbox"/>
Chelmonski's sign		
positive		<input type="checkbox"/>
negative		<input type="checkbox"/>

The spleen

Palpable		<input type="checkbox"/>
Impalpable		<input type="checkbox"/>
Respiratory mobility	<input type="checkbox"/> yes	<input type="checkbox"/> no
Hard		<input type="checkbox"/>
Soft		<input type="checkbox"/>
Tender		<input type="checkbox"/>
Painless		<input type="checkbox"/>

The pancreas

Palpable	<input type="checkbox"/> yes	<input type="checkbox"/> no
Tenderness on palpation	<input type="checkbox"/> yes	<input type="checkbox"/> no

The stomach, the small intestine

Palpable		<input type="checkbox"/>
Impalpable		<input type="checkbox"/>
Tenderness on palpation		<input type="checkbox"/>
positive		<input type="checkbox"/>
negative		<input type="checkbox"/>
Abdominal massess		
positive		<input type="checkbox"/>
negative		<input type="checkbox"/>

The large intestine

Palpable		<input type="checkbox"/>
Impalpable		<input type="checkbox"/>
Tenderness		

positive

negative

Abdominal masses

positive

negative

(Auscultation)

Peristaltic murmurs

Present

No murmurs

THE URINARY ORGAN

The kidney

(Inspection)

Protruding in the renal area

Visible

Invisible

Oedema in the renal area

Present

No oedema

(Palpation)

Palpable lower pole of kidney

Right yes no

Left yes no

Right kidney tenderness yes no

Left kidney tenderness yes no

(Percussion)

Goldflam's sign

Right - positive negative

Left - positive negative

The urinary bladder

(palpation, percussion)

Palpable over the pubic symphysis	<input type="checkbox"/> yes	<input type="checkbox"/> no
Palpable after urination	<input type="checkbox"/> yes	<input type="checkbox"/> no

THE ORGAN OF MOTION

The extremities

Symmetrical	<input type="checkbox"/> yes	<input type="checkbox"/> no
Joint mobility presence	<input type="checkbox"/> yes	<input type="checkbox"/> no
Congenital malformations	<input type="checkbox"/> yes	<input type="checkbox"/> no
Joint oedemas	<input type="checkbox"/> yes	<input type="checkbox"/> no
Joint deformations	<input type="checkbox"/> yes	<input type="checkbox"/> no
Joint tenderness on palpation	<input type="checkbox"/> yes	<input type="checkbox"/> no
Mobility restriction	<input type="checkbox"/> yes	<input type="checkbox"/> no

which joints

Vertebral column

Deformed	<input type="checkbox"/> yes	<input type="checkbox"/> no
Scoliosis		<input type="checkbox"/>
Lordosis		<input type="checkbox"/>
Kyphosis		<input type="checkbox"/>
Mobility restriction	<input type="checkbox"/> yes	<input type="checkbox"/> no

In this part of the textbook, the schemes of the anamnesis and physical examination have previously been presented. The neuromuscular system and psychological examination have been omitted since we do not have the appropriate didactic equipment.

The information concerning the patient, i.e. patient's medical documentation – is called the **CASE HISTORY**. It is just the beginning of the process; **CLINICAL REASONING** is still ahead of the students. We present aims and principles of clinical reasoning, which is supported by the appropriate examples.

Further stages of education of the medical profession, e.g. applying appropriate accessory laboratory tests and instrumental examinations, establishing the final diagnosis and planning the therapy are presented to the students during the successive years of the medical studies in the form of lectures and practical classes in the Clinical Departments.

References

1. *Bates Barbara, Nicley S. Lynn.*: Wywiad i badanie fizykalne. Kieszonkowy przewodnik. SPRINGER PWN, Warszawa 1997
2. *Chlebowski Jakub*: Choroby wewnętrzne. PZWL, Warszawa 1954
3. *Droszcz Wacław*: Diagnostyka chorób układu oddechowego. PZWL, Warszawa 1987
4. *Harrison T.R.*: Podstawy Medycyny Wewnętrznej. CZELEJ Lublin wydanie XIV, 2000
5. *Orłowski Witold*: Zasady ogólnej diagnostyki lekarskiej. PZWL, Warszawa 1994
6. *Szczeklik Edward*: Diagnostyka ogólna chorób wewnętrznych. PZWL, Warszawa 1966
7. *Tatoń Jan*: Ogólna Diagnostyka Internistyczna PZWL, Warszawa 1991

PRACTICAL GUIDELINES FOR CHEST EXAMINATION

(inspection, palpation, percussion, auscultation)

1. Areas and orientation lines
2. Inspection of the chest
 - symmetry assessment
 - chest shape assessment
 - infiltrations, tumours, pulsations
3. Palpation of the chest
 - infiltrations, tumours, pulsations

- subcutaneous emphysema
- mammary gland examination
- assessment of lymph nodes
- tenderness on palpation

4. Percussion

Types of percussion sounds

Symmetrical assessment of percussion sounds

- in the middle of the supraclavicular areas
- on the anterior wall of the thorax, in the middle of the second intercostal space
- in the fourth intercostal space, laterally to the midclavicular line
- in the sixth intercostal space, in the midaxillary line
- in the middle of the supraspinous areas
- in the middle of the left and right half of the interscapular area
- in the scapular lines, two fingers under the scapular angles

5. Examination of the respiratory system

Inspection:

- respiration rate
- breathing mode, phases of respiration

- respiratory mobility of the chest
- respiratory labor assessment

Palpation:

- respiratory extensibility of the chest
- pectoral (vocal) fremitus
- pleural friction rub

Percussion: detailed percussion

Percuss from the vesicular sound to the dull percussion sound.

Assess

- character of the percussion sound
- lungs' lines
- mobility of the lower lines

It is possible to find lateral and medial edges of the lungs' apices and the lower edges on percussion.

Lower lung borders:

- the right lung:
 - parasternal line, the fifth rib
 - midclavicular line, the sixth rib
 - midaxillary line, the seventh rib
 - scapular line, the eleventh rib
 - paravertebral line, the tenth rib
- the left lung:
 - parasternal line, the fourth rib
 - midclavicular line, the sixth rib
 - midaxillary line, the eighth rib
 - scapular line, the eleventh rib
 - paravertebral line, the tenth rib

Auscultation:

Auscultate the high tones with the membrane and low - with the funnel.

- Orientative, comparative auscultation (points of orientative percussion of chest)
- Detailed auscultation:
 - supraclavicular fossae
 - anterior intercostal spaces in medial, intermedial and lateral parts of each space
 - in midaxillary line in its superior, medial and inferior parts
 - supraspinous areas
 - interscapular area symmetrically in its superior, medial and inferior parts
 - infrascapular areas

Physiological respiratory murmurs:

- vesicular murmur
- bronchial murmur

Pathological respiratory sounds:

- rales
 - dry rales
 - sibilant rales (wheezes)
 - whirring rales
 - moist rales
 - coarse rales
 - medium rales
 - fine rales
- crepitating
- pleural friction rub (pleural crackle)

6. Heart examination

Inspection

- apex beat – limited bulge of the chest's wall, visible during the heart contraction near its apex. In healthy people with the correct construction of the chest, it appears in the fifth left intercostal space, 1,5 cm medially to the left midclavicular line. It is most frequently visible and palpable, regular, covered with a pulp of the middle finger and it is compatible with heart beat rate and pulse; its left line is simultaneously the left line of the cardiac dullness.
 - heartbeat

- pulsation in the epigastric fossa (pathological sign)
- filled jugular veins

Palpation

- apex beat
- fremitus
- pleural friction rub

Percussion

- absolute cardiac dullness (soft percussion)
 - superior line: upper edge of the fourth left rib
 - left line: 1,5 cm medially from the midclavicular line, almost upright
 - right line: along the left sternal line
 - lower line: in the fifth left intercostal space, 1,5 cm medially to the left midclavicular line
- relative cardiac dullness (strong percussion)
 - superior line: in place of attachment of the third ribs to the sternum or in the third intercostal space, then it heads downwards and it runs on the fourth rib in the left half of the chest, nearby the left midclavicular line
 - left line: from the fourth rib on the right midclavicular line in the left half of the chest upright and down to the fifth intercostal space or the sixth rib
 - right line: in the left sternal line or along the right sternal line

Auscultation

While auscultating, pay attention to heart beat rate and regularity of heart sounds. Assess the sound volume, sonority and accentuation, intervals between the first and second sounds and between the second and the following one. Search for split and bifurcated sounds, accidental sounds and murmurs.

Projection of the valves:

- mitral valve: attachment of the fourth left costal cartilage to the sternum
- aortic valve: on the sternum, at the attachment of the third rib to the sternum

- pulmonary valve: in the second left intercostal space by the sternum
- tricuspid valve: its projection crosses the sternum from the third left attachment to the fifth right attachment of the costal cartilages to the sternum

Points of heart valve auscultation (following the order of auscultating):

- mitral valve: on the heart apex
- aortic valve: in the second right intercostal space by the sternum
- pulmonary valve: in the second left intercostal space by the sternum
- tricuspid valve: at the attachment of the fifth right costal cartilage to the sternum

Heart sounds

- sound I (low, long), appears at the beginning of ventricular systole. It is the result of vibrations caused by sudden closing of left and right atrio-ventricular valves
- sound II (high, short), audible after the end of ventricular contraction. Caused by vibrations of closing semilunar aortic and pulmonary valves, immediately after ventricular diastole (may be bifurcated - physiology)
- sound III (soft, low), appears after about 1/3 of diastolic time. It is probably the result of vibration of ventricular walls due to rapid filling with blood at the beginning of the diastole
- sound IV appears exactly before sound I, when the pressure in the atria is high or if the walls of the ventricles are rigid because of their hypertrophy. Filling the ventricles during contraction of the atria causes the sound. Rarely is it audible in physiological conditions.

All the audible sounds in the area of the heart between the beginning of sound I and sound II are called **systolic**, while those following the beginning of sound II and before sound I are called **diastolic**.

PRACTICAL GUIDE TO ABDOMEN EXAMINATION

The abdomen examination includes **inspection, palpation, percussion** and **auscultation**.

The inspection of the abdomen wall is performed in patient supine position; its aim is to evaluate:

- ***abdominal wall***: skin and subcutaneous fat tissue, discoloration, scars related with surgery, pathological skin changes, enlarged veins and the distribution of fat tissue.
- ***the shape of abdominal wall***: increased or decreased circumference of the abdomen.

Increased abdominal size is observed in:

- obesity,
- edema of the abdominal wall,
- abdominal distention,
- non-encapsulated fluid inside the abdomen cavity,
- tumors,
- hernias,
- pregnancy.

Decreased abdominal size is observed in:

- wasting diseases.

- ***peristalsis movements*** – the symptom of intestine bloating;
- ***pulsations***
- ***the relations between abdominal movements and respiration***

Abdomen palpation: is performed in patient supine position and either at his left or right side. One should not use the fingertips during the palpation; the hand lying flat on the skin surface should only be used for the palpation. The pressure applied should be evenly distributed throughout the entire hand surface, moving towards the fingertips only at times when the abdominal masses are sought. The pressure should not be strong and cause any pain.

The palpation procedure should be started at painless sites proceeding usually towards the left iliac fossa.

● **Palpation allows for the identification of:**

- the extent of abdominal wall tension,
- diffused or local tenderness,
- abdominal masses
- the presence of fluid or gas in the peritoneal cavity,
- the abnormalities of sensory perception in the skin.

The abdominal wall tension is associated with the muscle tone of the abdominal wall muscles and the accumulation of subcutaneous fat tissue.

Increased abdominal wall tension is found in the case of

- accumulation of fluid or gases in the abdominal cavity,
- increased muscle resistance due to diffuse or localized pain, i.e. in peritonitis.

Decreased abdominal wall tension is found in:

- wasting syndromes,
- chronic distention of abdominal wall: ascites, frequent pregnancies.

In case of tenderness on palpitation the exam should include determining if the rapid release of hand pressure is accompanied by increased tenderness compared with the pain that is elicited by applying pressure alone. This is Blumberg sign, which provides evidence of acute peritonitis.

The presence of peritoneal fluid can be confirmed using the bloating/shaking method. It involves hitting the abdomen side with the fingertips and sensing the pressure wave of fluid at the opposite side.

● **Abdomen percussion:** under physiological conditions the percussion sound in the abdomen is of tympanic resonance, which is related with the extent of gut and stomach distension with gas.

THE EXAMINATION OF ABDOMEN ORGANS

Liver examination

Liver percussion should determine the organ borders. The upper liver border is the same as lower right lung border, whereas it fuses with cardiac dullness to the left side. The lower liver border runs: between the tenth rib and the eleventh rib in the right axillary line, just below the costal chest border in the middle clavicular line, in the medial line– in the middle of the distance between the xiphoid and umbicullus, between the parasternal line and middle clavicular left line – just below the costal chest border.

Liver palpation is performed with the right hand placed flat under right costal chest border, parallel to the long body axis, then applying pressure at the depth of inspiration in an attempt to move under the costal border in the right middle clavicular line and towards its right side. In normal conditions, the lower liver border is not touched. During the respiration, the lower liver border is slightly moving down and upwards.

If the liver edge can be detected on palpation, some additional features have to be determined as there are various abnormalities related with specific diseases:

- **Liver border**

the location and the course of liver edge to determine:

- whether it is sharp or round,
- whether it is smooth or knobby,
- the mobility of the edge,
- tenderness or pain.

- **Liver surface**

- smooth,
- even,
- painful

The gallbladder under normal conditions cannot be palpated. An enlarged gallbladder is felt as a pear-shaped formation that is connected to the liver and mobile on respiration.

The strongest pain on palpation is related with inflamed gallbladder with accompanying Chelmoński's sign, which involves eliciting pain sensation during inspiration at the time of slapping patient's right costal border.

Spleen examination

The spleen is located under the left chest costal border and reaches the spine with its posterior border at the level of thoracic vertebrae X, and reaching the medial axillary line with its anterior border between the ninth rib and the eleventh rib. The long spleen axis runs obliquely along rib X from the posterior and upper side forward and downwards.

Spleen percussion: is performed in semi lateral position i.e. the intermediate position between lying on the back and on the right side. The silent percussion of the inferior and anterior (directly adjacent to the chest wall) sides of spleen is performed.

Spleen palpation: is performed with the right hand placed under the left costal margin perpendicularly to the margin while asking the patient to breathe deeply. During deep inspiration and expiration, the fingertips are inserted below the costal margin and the attention is paid to the spleen border, which emerges over the fingertips in the case of spleen enlargement. Under normal conditions the spleen cannot be palpated. In case of the enlargement of the spleen, special attention is paid to:

- *spleen size* – minor enlargement from several centimeters, as in infectious diseases, lymphatic leukemia, hemolytic anemia; marked enlargement may reach the pubic symphysis, as in myeloid leukemia;
- *spleen surface* – smooth, uneven, soft, hard
- *spleen tenderness* – spontaneous, i.e. in spleen infarction

Pancreas examination

The pancreas is located at the level of lumbar vertebrae I –II. The pancreas head is lodged within the curve of the duodenum; its corpus runs across the descending aorta and its tail reaches the left kidney. The physical exam of pancreas is difficult as the access is limited and it is not available for percussion or palpation.

The examination of the gut

The GI physical examination is commonly started from the sigmoid colon. The fingers are placed in the left iliac fossa, perpendicularly to the long sigmoid axis, and on superficial

and deep palpation the sigmoid can be felt as a cylinder of a few centimeter-diameter. The upper region of the colon is examined including the consecutive parts of the spleen flexure, transverse colon and hepatic flexure down towards the caecum. Usually, each consecutive region is not palpable, as it is dependent on the intestine luminal distention, its wall tension and the abdominal wall tension.

Clinical reasoning – quality and quantification

Skills to be mastered during classes:

- step by step analysis of a diagnostic process; concepts: data analysis, medical problems, diagnostic hypothesis;
- determination of a symptom significance and accessory investigations to confirm or reject a diagnostic hypothesis; 2 x 2 table; sensitivity, specificity, positive and negative predictive value; pre-test and post-test probability

1. What is a clinical reasoning?

- an analytical and critical thinking ability in the diagnostic and therapeutic process;
- a way of solving clinical problems;
- an ability to use theoretical knowledge – beginning with patient's complaints and symptoms, forming a diagnostic plan, which would result in verifying the diagnostic hypothesis and establishing the diagnosis.

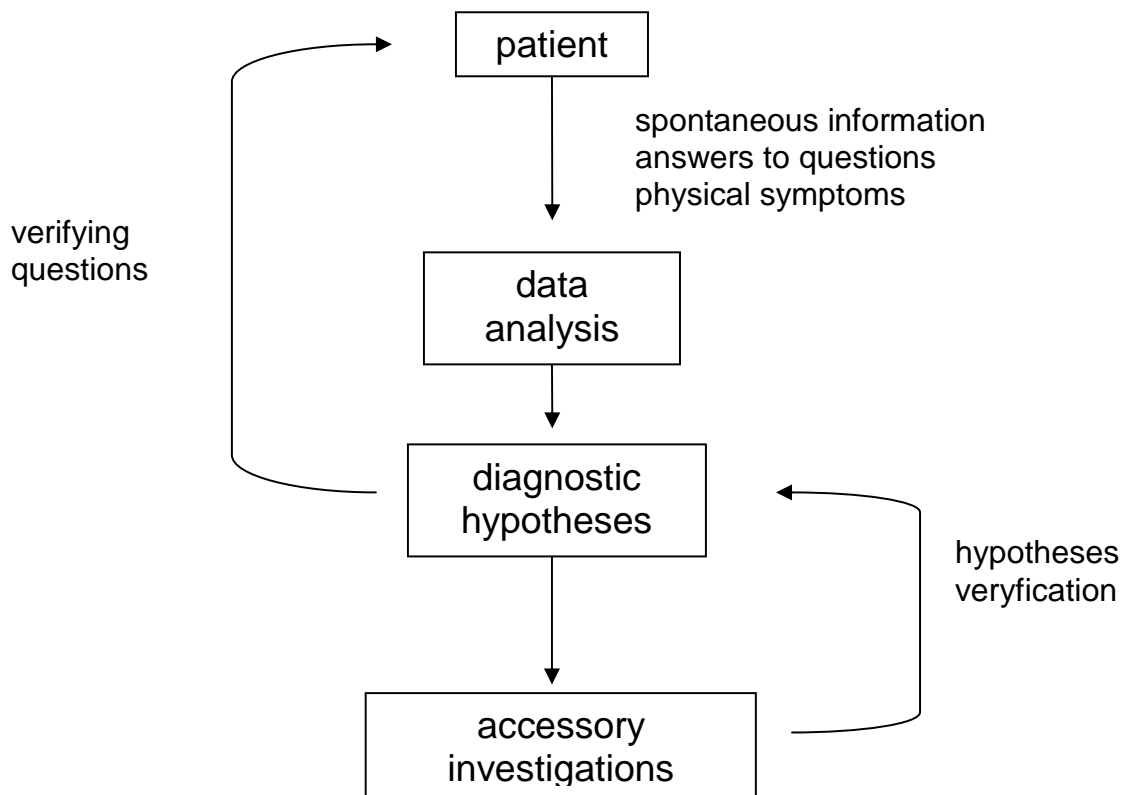
2. Clinical reasoning is a cyclic process!

The doctor follows the procedures concerned with:

1. eliciting medical history
2. physical examination
3. accessory investigations
4. differential diagnostics
5. establishing the diagnosis

However, this convention seems too simplified. Usually, deviations in history taking and physical examination result in establishing a preliminary diagnostic hypothesis (or hypotheses). Further action is undertaken: diagnostic examinations are done considering the presumptive diagnosis. New results that are obtained meanwhile (results of the accessory investigations, new data coming from medical history or the physical examination) contribute to confirming the diagnosis or rejecting the tentative diagnosis in search for a new one. An alternative hypothesis requires further examinations and results in establishing the final diagnosis.

This way of thinking may be presented as follows:



The presented mental process may be termed as a hypothetical-deductive one.

Various analytical methods may be used and combined in one diagnostic process:

- knowledge / experience enables to recognize disease “pattern” (usually used by GPs to establish a diagnosis immediately; in this method, a diagnostic process ends with defining and treating the clinical syndrome, e.g. a typical clinical syndrome of pyelonephritis, purulent tonsillitis (sore throat), acute sinusitis. In such cases diagnostic hypotheses are not usually verified (except for *ex iuvantibus* – based on the treatment results) e.g. after successful management of purulent tonsillitis with penicillin-derivatives, the doctor can conclude that the disease has been caused by streptococcal infection. Occasionally, a characteristic syndrome or a group of syndromes enable us to establish the final diagnosis (a diagnostic hypothesis, which does not need to be confirmed), e.g. typical syndromes accompanying *herpes zoster* infection (a sign or a group of signs, which are pathognomic of a given disease).

- systematic and detailed collection of the information/ data (including detached or/and atypical disease syndromes), when there are many possible and equally important hypotheses and no “dominant” diagnosis (e.g., diagnosing the fever of unknown origin).
- following an established algorithm; e.g., diagnosing anemia or the presence of fluid in the pleural cavity that is accompanied by an isolated medical problem)

3. *Clinical thinking (following the scheme) – problem-solving approach*

The diagnostic process should be organized and analyzed logically as presented below:

1. Eliciting information from the patient (history – syndromes, physical examination – signs, results of available accessory investigations)
2. List of **activating data** – all the abnormal results obtained from subjective and objective examinations, including medications that have been received, results of the accessory investigations, risk factors, finally, patient’s demands; it is the doctor who decides, which syndromes can be classified as abnormal.
3. List of **medical problems** – the principles:
 - a set of data, which (according to the diagnostician) seem to be associated with the same pathology (what are the causes that their real relation has not been checked)
 - one or several activating data contribute to solving the problem
 - if a syndrome (activating data) can have several sources, it should become a distinct problem
 - each drug, risk factor or patient’s requirement should be regarded as a separate problem
4. Analysis of the listed problems – creating **diagnostic hypotheses** - an attempt to explain patient’s ailments qualified as "problems" by assigning them to a given pathology, disease.
5. Planning actions – sort and order of accessory investigations aiming at confirmation or rejection of the diagnostic hypothesis.

General note:

It seems that the critical point in analyzing a clinical case is to convert the activating data into medical problems. It is obvious that a student, having an initially narrow clinical knowledge, will be incapable of associating the activating data with problems and, as a result, the list of clinical problems will follow the list of activating data (as many clinical problems are considered activating data). On the other hand, an experienced doctor, who knows and is able to identify a set of syndromes that accompany a certain disease, will be able to link all the activating data with one medical problem, which shows perfectly well how important both

the knowledge and clinical experience (based on diagnosing disease syndromes) is. It markedly contributes to the advancement of the diagnostic process.

4. Example of a clinical case analysis

A 43-year-old patient has visited the outpatient clinic:

Anamnesis (history)

Main complaints: 2-weeks history of aggravating pain in the precordial pit, mainly in the morning and after an irritation. Patient noticed occurrence of an increased appetite – meals bring relief to the pain, nothing in common with exertion. That morning an onset of a severe pain made the patient visit a doctor. No vomiting. Regular bowel movements (once in 24 hours), no abnormalities, no melaena stools. The described disorders occurred for the first time in his life. He has been treated for hypertension (the highest measured BP value was 200/120); actually receiving metoprolol (50 mg q. 12 hr, orally). He was treated with acetylsalicylic acid for abdominal pain (300 mg q. 8-24 hr, 2 wks).

Besides:

- has smoked 30 cigarettes a day for 25 years
- family history: father after infarction at the age of 58, mother suffering from peptic ulcer
- drives for a living, married, with 2 children

Physical examination:

body temperature - 36.8 C

weight – 80 kg

height - 1.76 m

nodes: NAD (no abnormalities detected)

C.V.S.: heart rate 96/min., regular; heart sounds loud, normal accentuation; BP110/70 mmHg;

R.S.: respiratory rate - 26/min., pectoral/vocal fremitus symmetrical, vesicular resonance, vesicular murmur – normal;

Abd: hard, marked tenderness in the epigastrium, Blumberg sign positive, no abdominal masses on palpation, tympanic resonance over the whole abdominal cavity - diminished hepatic dullness, peristalsis detectable, smooth-edged liver protruding 2 cm below the costal arch, Goldflam's and Chełmoński's signs negative.

Extremities: peripheral pulse compatible with heart beat, palpable on peripheral arteries.

Activating data:**Anamnesis:**

1. Abdominal pain
2. Hypertension
3. Metoprolol
4. Acetylsalicylic acid
5. Nicotinism
6. Father – ischemic heart disease (IHD)
7. Mother– peptic ulcer

Physical examination:

8. Tenderness in the abdominal area – Blumberg sign - positive
9. Board-hard abdomen
10. Tachypnoe
11. Diminished hepatic dullness

Problem list with assigned activating data:

1. Acute abdomen: 1, 8, 9, 10 and 11
2. Hypertension: 2
3. Medications: 3, 4
4. Nicotinism: 5
5. Family history: 6, 7

Problem analysis:

No doubt, the main problem that needs immediate diagnosing seems to be the set of syndromes called „acute abdomen” syndromes. With such accompanying signs, a disease of upper alimentary tract may be suspected, e.g. duodenal ulcer, with perforation (the first of the possible diagnostic hypotheses) due to treatment with non-steroid anti-inflammatory drugs (NAID) may have occurred.

Proceeding:

One of a readily available examination is an X-ray of the abdominal cavity, in which the air under the dome of the diaphragm can be detected. This radiological syndrome could confirm the diagnostic hypothesis and substantiate initiation of the treatment – surgical

intervention. However, how would a normal X-ray imaging influence our reasoning – is it enough to reject the diagnostic hypothesis?

On the one hand, the presence of this sign confirms our hypothesis (with great probability); on the other hand, we cannot reject this hypothesis because of lack of this syndrome. It is a problem: what should we do if the result of this exam does not contribute to our diagnostic process?

5. Quantification in clinical understanding – verification of the diagnostic hypothesis:

During the diagnostic process, information is gathered, including: patient’s complaints (syndromes), objective signs, results of accessory examinations and tests in order to establish the diagnostic hypothesis, then to confirm or reject it. Asking the patient some questions about certain signs (e.g. if the pain in chest is associated with coughing - when pleurisy is suspected), searching for certain signs (e.g. Courvoisier’s sign in case of pancreas head cancer suspicion), performing laboratory tests, image studies or functional tests (e.g. positive exercise test in diagnosing ischemic heart disease), we usually receive negative or positive result. The matter of the clinical understanding is an evaluation of the results, considering if it is contributory to verification of the diagnostic hypothesis. Suppose we have examined 100 patients, who were admitted with a similar clinical problem – stomach/duodenal perforation suspicion. In each case, a review abdominal cavity X-ray was performed. Results are presented in a 2 x 2 table:

	Study group – 100 subjects	
air presence below the diaphragm	perforation - 63	no perforation - 37
+	50	1
-	13	36

How do we know that perforation occurred in one group of patients and did not occur in the others? Based on the gold diagnostic standard, which exploratory laparotomy seems to be, a part of patients were observed because acute abdomen syndromes withdrew and they were diagnosed in another way – e.g. gastroscopy.

What conclusions can be drawn from the performance of the clinical exams?

Perforation, the reason of this medical problem frequently accompanies such a set of syndromes – preliminary probability of this disease reaches 63% - there are also chances that our patient suffers from perforation, without carrying any tests.

In how many patients the air is present below the diaphragm?

Fifty out of 63, which accounts for 79% - it is the **sensitivity** of our accessory examination in diagnosing perforation (21% of patients with perforation may receive false negative result!)

How many patients without perforation do not have this syndrome?

Thirty six out of 37, which accounts for 97% - it is the **specificity** of our accessory exam in diagnosing perforation (only 3% of patients without perforation would receive false positive result!)

What is the probability that a patient with a positive result has a perforation?

Fifty out of 51, which accounts for 98% - it is a **positive predictive value** in diagnosing perforation.

What is the probability, that a patient with negative result does not have a perforation?

Thirty six out of 49, which accounts for 73% - it is a **negative predictive value**.

In conclusion, the air below the diaphragm in the X-ray image of the abdominal cavity which is accompanied by typical clinical picture, increases probability of perforation from 63% to 98% and is insufficient to reject this diagnostic hypothesis.

The above example shows practical application of an examination with a relatively high specificity and low sensitivity, in verification of the diagnostic hypothesis. Noteworthy, the selection of a test with high specificity enables us to confirm the diagnostic hypothesis thanks to its high positive predictive value (relatively small amount of false positive results effects in high positive predictive value). Similarly, option of a test with a high sensitivity enables to reject the diagnostic hypothesis based on a negative result. Unfortunately, examinations with a comparable high sensitivity and specificity are rare.

6. Practical examples:

I. We should further analyze what diagnostic value in diagnostics of ischemic heart disease (IHD) can be attributed to a symptom of retrosternal pain (burning, pressing) which appears on exertion – with what probability, based on this symptom, can we diagnose this disease, keeping in mind that its sensitivity reaches 80% and specificity - up to 70% (hypothetic values):

- a) in a group of 50 men, aged over 50, IHD frequency reaches 20% (hypothetic value), estimated IHD probability in case of the particular symptom is:
20%, 40%, 60%, 100%
- b) in a group of 50 women under 50, IHD probability reaches 1% (hypothetic value) estimated IHD probability in case of this symptom is:

1%, 3%, 5%, 10%

II. A 50-year-old woman with a positive mammography result, performed after reading an article about breast cancer prevention is seeking medical advice. What is the probability that she really suffers from mastopathy, if breast cancer incidence (hypothetic data) in this age group reaches 1%, mammography sensitivity- 90%, specificity- 80%?

1%, 4%, 8%, 32%

The same situation, a woman underwent the mammography as a result of a breast nodule discovered on palpation. What is the estimated breast cancer probability if the sensitivity and specificity of this symptom reach 70%; what is breast cancer probability based on a positive mammography result?

1%, 10%, 20%, 30%

The electrocardiographic examination, performance and analysis

¹ Department of Invasive Cardiology, I Chair of Cardiology and Cardiac Surgery, Medical University of Łódź

² Department of Cardiology, I Chair of Cardiology and Cardiac Surgery, Medical University of Łódź

An electrocardiogram (ECG) is a recording of the cardiac electrical activity as a graph or a series of wave lines on a moving strip of graph paper or displayed on a monitor.

I/. History of electrocardiography

- **1887** – an English physiologist Augustus D. Waller, who worked in St. Mary's Hospital in Paddington, London published the first electrocardiogram of a human being, which was performed using a capillary electrometer.
- **1895-1901** – a Dutch physiologist Willem Einthoven developed the technique of recording the activity of the heart; he introduced the term “electrocardiography” and assigned the letters P, Q, R, S and T to five basic deflections. In 1924 he was awarded the Nobel Prize for his discovery.

II/. Electrophysiological grounds of ECG

Electrocardiogram is a concise record of the changes of potentials during depolarization and repolarization of myocardial cells. Electric changes at the level of a single cardiomyocyte are as shown in figure 1.

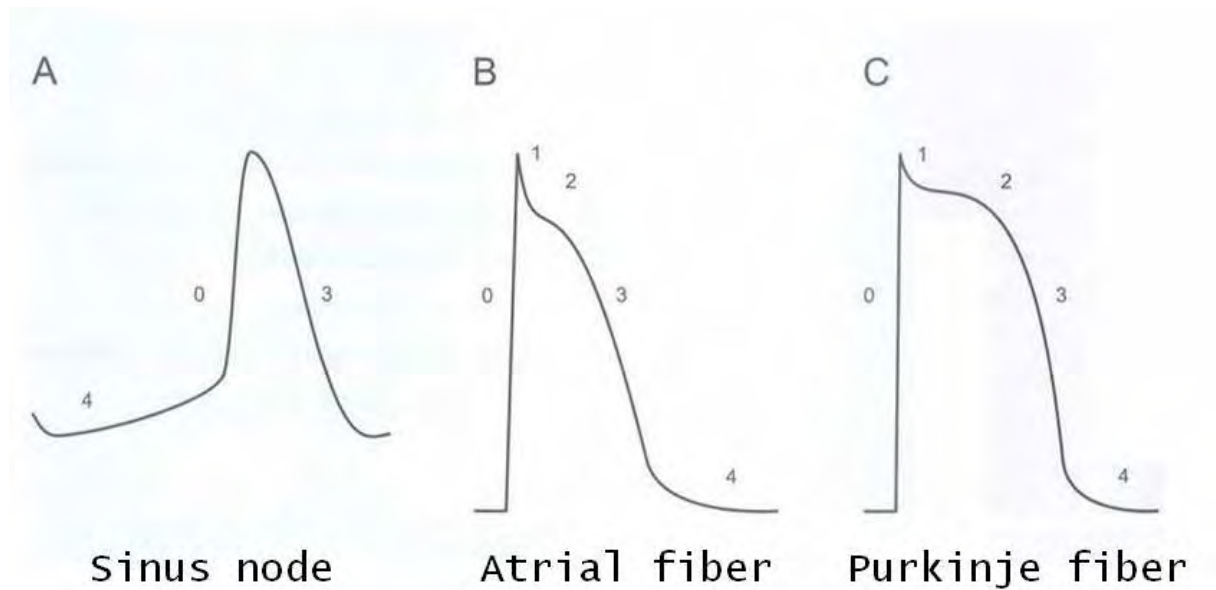


Fig. 1. Functional potential – diagram

Knowledge of these phenomena is essential to understand the characteristic picture of ECG curve (waves, intervals, segments).

Resting potential

The interior of a myocardial cell is electrically negative in relation to its exterior and the potential of its interior is about -90 mV. The state in which intracellular negative ions predominate over the positive charge outside is called the 'cell polarization' and it is defined as the resting membrane potential.

The resting membrane potential is maintained by sodium ions at a higher concentration outside the cell and accumulation of potassium ions inside cardiomyocytes. The cell membrane is impermeable for sodium ions during the resting state. They do not penetrate the cell by passive diffusion driven by the gradient of concentrations. In the resting state, cell membrane is however, permeable for potassium ions and the existing difference of these ion concentrations between the cell interior and the extracellular space directs the diffusion outside, counteracting the potential difference. The difference of the potential between the cell interior and the intercellular space is maintained enzymatically – actively by $\text{Na}^+ \text{K}^+$ ATP-ase, which transports these ions against the gradient of concentrations and the potentials of electric

charge. Na^+ K^+ ATP-ase extrudes 3 Na^+ for every 2 K^+ that are introduced into the cell; the 3:2 ratio contributes to the generation of the membrane potential.

Action potential

The change of the membrane potential after a stimulus is called an action potential. A stimulus affecting polarized myocardial cell (physiologically generated at and arriving from the sinoatrial node) changes the membrane permeability for sodium ions. Sodium ions penetrate the cell interior and decrease negative potential to the value of about -65 mV (the so-called threshold potential). When the value of the threshold potential is exceeded, sodium channels open and the channels facilitate the rapid, free flow of sodium ions into the cell and the cell is instantly and entirely depolarized. At the value of -40 mV calcium channels open and at the moment of the cell stimulation, the potential increases fast to reach positive values (to about $+30$ mV) – and the depolarization occurs. Slow return to the initial stage is termed repolarization.

The cardiac action potential is divided into 5 phases:

- **Phase 0 – the phase of rapid depolarization** – electric excitation, decreasing negative membrane potential to the value of about -65 mV, leads to rapid increase in cell membrane permeability for sodium ions. The fast inward sodium current is the main ionic shift conditioning rapid depolarization of the majority of myocardial cells. Simultaneously, the inflow of calcium ions into the cell starts from the value of membrane potential of about -40 mV. Slow inward calcium current stimulates calcium ions release from endoplasmic reticulum, which initiates muscle fibre contraction.
- **Phase 1 – early rapid repolarization phase** – depends on the inflow of chloride ions into the cell
- **Phase 2 – the “plateau” phase of the cardiac action potential** – this is the phase of slow repolarization. In a complicated exchange of ions across the cell membrane, calcium slowly enters the cell through calcium channels as potassium continues to leave the cell. The membrane potential remains relatively stabilized.
- **Phase 3 – is the terminal phase of rapid repolarization**, during which the inside of the cell becomes markedly negative. From the value of about -65 mV the permeability

of cell membrane for sodium decreases again and ionic pump again transports Na^+ out of the cell and K^+ back in.

- **Phase 4 – the resting phase** – the ionic pump is still active. To stimulate the cell the resting potential must be repolarized to the value -65 mV . The level to which a cell must be repolarized before it can be depolarized again is called the threshold potential and the stimulus capable of stimulating the cell – the threshold stimulus.

III/. The structure of the stimulation – conduction system

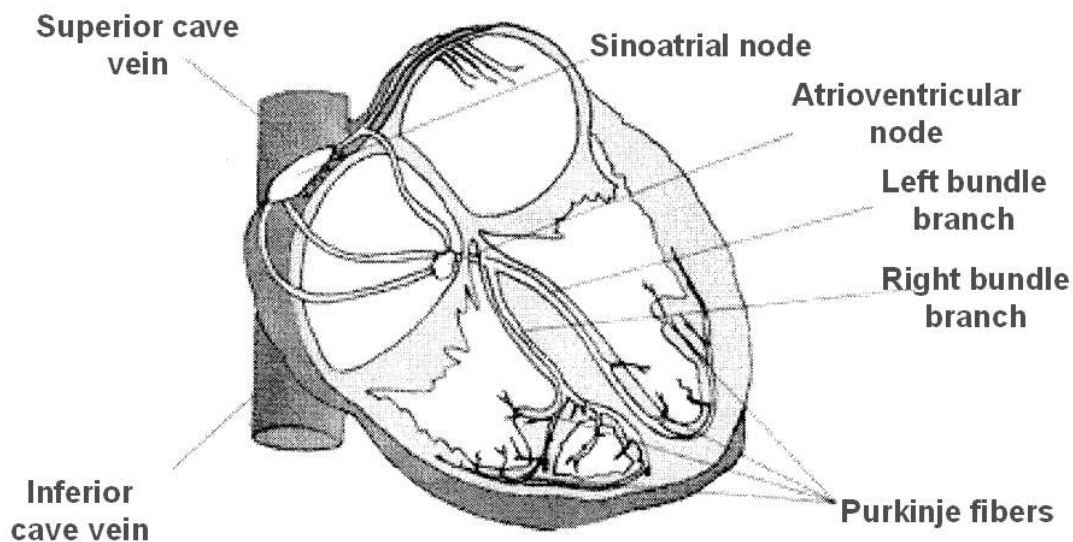


Fig. 2. The stimulation-conduction system

Sinus node – located at the junction of the superior caval vein with the morphologically right atrium

Atrio-ventricular node – located at septal leaflet of tricuspid value, close to the coronary sinus orifice.

His bundle – in the membranous part of the interventricular septum

Left bundle branch – is divided most frequently into 3 divisions:

- left anterior fascicle
- left posterior fascicle
- septal – left branch extension

Right bundle branch – along the right side of the interventricular septum.

Within the action potential of stimulation – conduction system

- in phases 0, 1, 2 and 3 to the level of membrane potential (-55 ÷ -60 mV) – the myocardial cell does not react to any stimuli – absolute refractory period
- from -55 ÷ -60 mV to about -90 mV – relative refractory period
- directly after obtaining full excitability near the end of T wave, a stimulus weaker than is normally required can depolarize cardiac cells. This short portion of repolarization is called the supernormal period. Also in the second half of phase 3 there comes to vulnerable period of repolarization (vulnerable phase) during which a stimulus may produce severe arrhythmias – the ventricular tachycardia or ventricular fibrillation.

IV/. ECG Leads

A lead – is an electric circuit consisting of a galvanometer connected through electrodes with two points of electric field.

In everyday life a lead is regarded as a single ECG curve (although it is a certain mental shortcut).

Two groups of leads are distinguished: bipolar and unipolar.

In case of bipolar leads both electrodes are attached at the points of potentials which are measured. When unipolar leads are registered, a positive electrode is located at the site of the investigated potential (the *tracing electrode*, while the negative one - at the site distant from the investigated tissue of zero potential / *reference electrode*).

Standard complete ECG specifies 12 separate leads:

- 3 limb leads, bipolar (classic) – determined as: I, II, III
- 3 limb leads, unipolar – determined as: aVR, aVL, aVF

- 6 precordial, unipolar leads – determined as: V_1 - V_6

The diagram of **classic limb bipolar leads** (Einthoven's) are presented in figure 3.

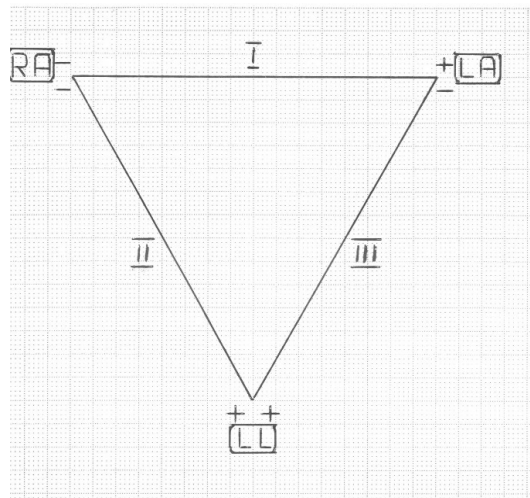


Fig.3 Einthoven's triangle diagram

These leads record the difference of potentials between the body areas located in the same distance (approximately) from the heart. In a stationary ECG, the electrodes are attached to forearms and lower leg, whereas during exercise test or 24 h Holter monitoring all the electrodes are attached to the chest.

The colours of the lead endings and the places of attachment of the electrodes are the following:

- N – black (right lower leg or the region of right anterior superior iliac spine)
- R – red (right forearm or the region of right shoulder)
- L – yellow (left forearm or the region of left shoulder)
- F – green (left lower leg or the region of left anterior superior iliac spine)

The measurement of the difference of the potentials (in mV) is performed between these electrodes:

- lead **I** – the difference of potentials between the electrodes placed on “left arm” and “right arm” (LA-RA)
- lead **II** - the difference of potentials between the electrodes “left foot” and “right arm” (LF-RA)

- lead **III** - the difference of potentials between the electrodes “left foot” and “left arm” (LF-LA)

(in American literature these are called: L₁, L₂, L₃ – from English – limb)

Unipolar limb leads (in Goldberger modification) are obtained using a positive (active) electrode (one pole) attached to one of the three extremities (right arm, left arm or left foot) whereas the central terminal is made by connecting the other two extremity electrodes and the second pole of the lead far from the investigated tissue of zero potential. These leads serve for measuring the absolute potential at a given point.

The three extremity electrodes are attached as follows to obtain the three augmented (unipolar) leads:

- lead aVR – the positive electrode is attached to the “right arm” (RA)
- lead aVL – the positive electrode is attached to the “left arm” (LA)
- lead aVF – the positive electrode is attached to the “left foot” (LF)

the “zero electrode” is an attachment of the remaining two electrodes (and its electric potential is zero).

ATTENTION!

All limb leads (bi- and unipolar) are in the frontal plane and classic lead I belongs both to frontal and transverse (horizontal) plane; precordial (unipolar) leads are in the transverse plane.

Precordial unipolar leads (Wilson’s) are recorded from 6 typical attachments of the electrodes on the chest (fig. 4):

- V₁ – red – right side of the sternum in the fourth intercostal space
- V₂ – yellow – left side of the sternum in the fourth intercostal space
- V₃ – green – midway between V₂ and V₄
- V₄ – brown – midclavicular line in the fifth intercostal space
- V₅ – black – anterior axillary line at the same level as V₄

- V₆ – violet – midaxillary line at the same level as V₄.

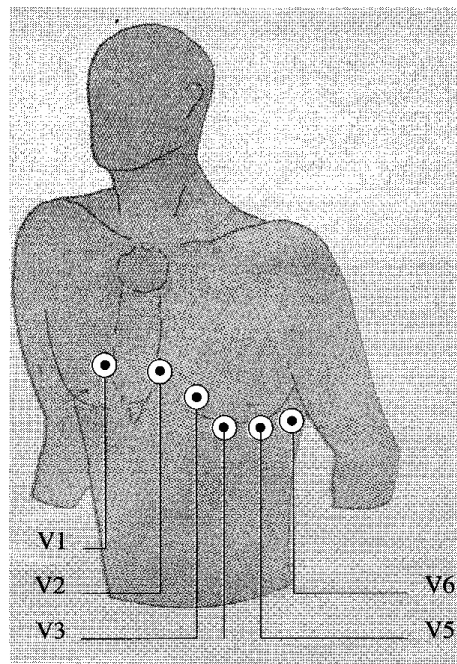


Fig. 4. The diagram of precordial electrode placement

Additionally:

- **7 special leads** are distinguished (supplemental attachments):
 - 3 leads from the cardiac posterior wall – V₇-V₉
 - 4 right-ventricular leads – V_{3R}-V_{6R}

Arrangement of special leads:

- V₇ – is level with V₄-V₆ in the left posterior axillary line
- V₈ – is level with V₄-V₆ at the left midscapular line
- V₉ – is level with V₄-V₆ at the left spinal border
- V_{3R}-V_{6R} – mirror reflection of V₃-V₆ leads but on the right side of the chest.

The so-called **ECG set** records additionally 12 precordial leads (particularly in case of myocardial infarction – the leads are recorded two intercostal high and the leads two intercostal spaces lower: V₁'' -V₆'' – the so called high and the leads two intercostal spaces lower: V₁' -V₆' - the so called low).

All these leads can be grouped topographically and they describe particular walls of the heart.

Thus:

- leads II, III, aVF – “show” the heart inferior surface,
- lead V₁ – “shows” RV anterior wall and demonstrates P wave very well,
- leads V₂-V₄ – left ventricular anterior wall,
- leads V₅-V₆ and aVL – left ventricular anterior lateral wall,
- leads V_{3R} and V_{4R} – right ventricle and leads V₇-V₉ – left ventricular posterior wall.

Oesophageal leads are a completely different group of records (placing a multi-pole electrode in oesophagus, which borders with left atrium at a depth of 35-40 cm from the teeth line, an important instrument is obtained in the diagnostics and therapy of arrhythmias, mainly tachycardia) – fig. 5.

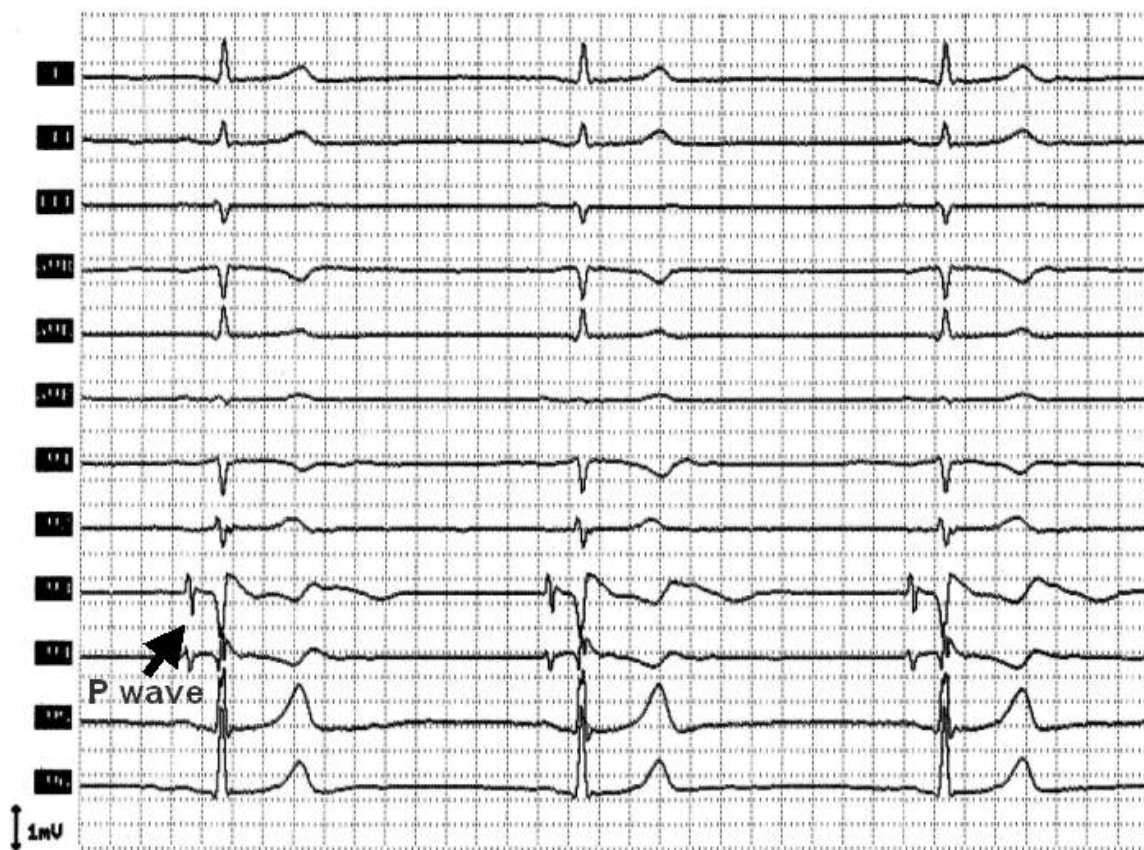


Fig. 5. Transoesophageal ECG

Endocardiac leads (fig. 6) – obtained using electrodes inserted into the cardiac cavity during invasive electrophysiological study (EPS)

- HRA – recording potentials from high right atrium (RA)
- EpH - recording potentials from the region of the bundle of His
- CS - recording potentials from the coronary sinus
- RVA - recording potentials from right ventricular apex
- other leads – dependently on definite needs in the course of the examination

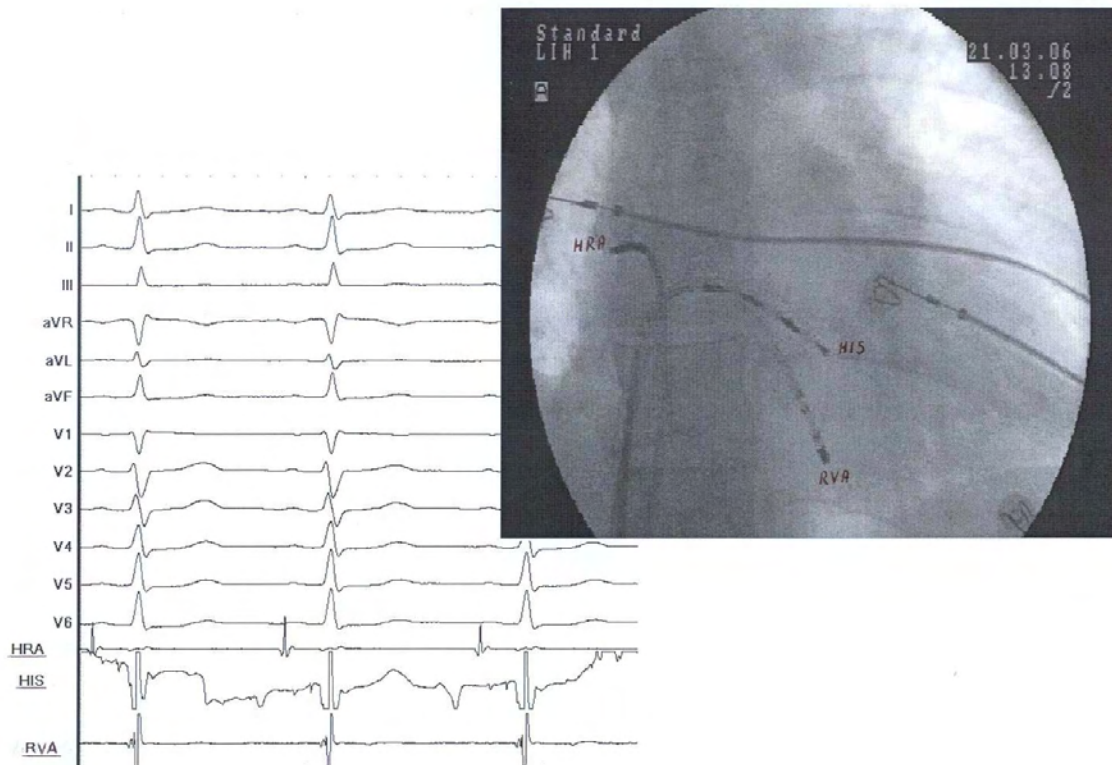


Fig. 6. ECG (a record from numerous endocardiac leads)

V/. Analysis of ECG curve

Before starting an adventure with the analysis of real ECG records, the essentials of an electrocardiographic ABC must be known. The beginnings may be difficult but...the end crowns the work.

This is an example of normal electrocardiogram (fig. 7)

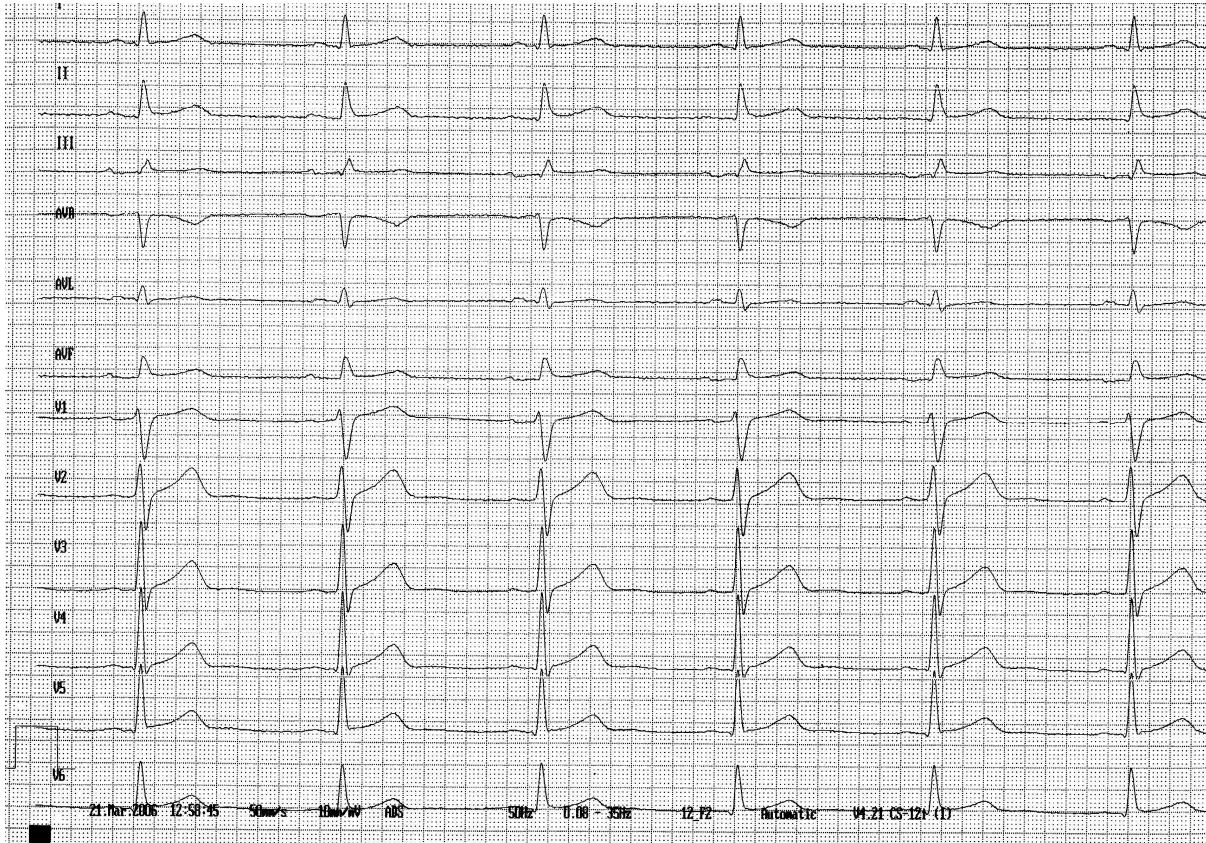

Fig.7. Normal ECG

1/. Waves, segments, intervals (fig. 8)

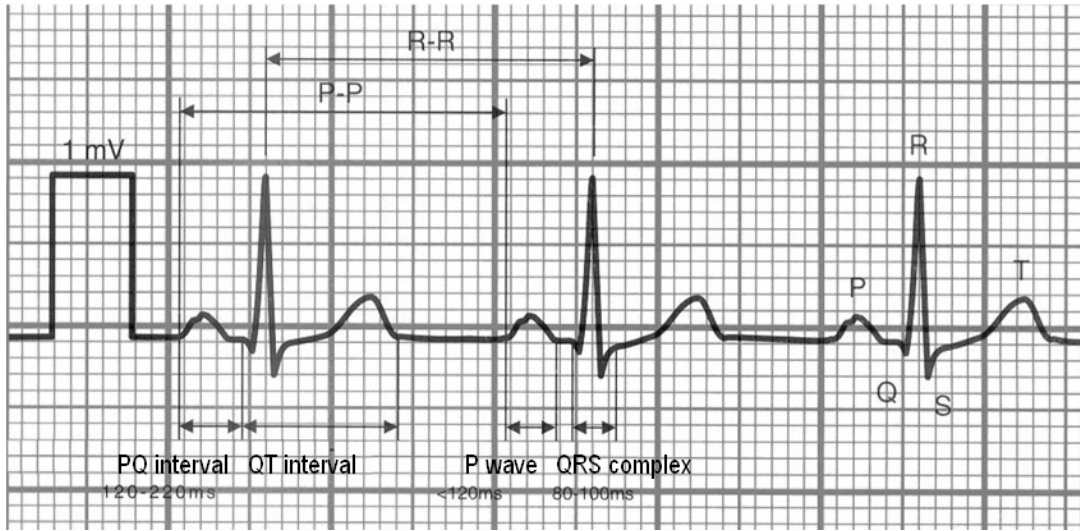


Fig. 8. Waves, segments and intervals in ECG

The ECG curve consists of repeatable elements that are **PQRST complexes**.

Each complex includes:

a/ **waves** – each deflection of ECG curve up or down the isoelectric line; the following waves are distinguished:

- **P wave** – a record of atrial depolarization
- **Q, R, S waves** – the QRS complex – a record of ventricular depolarization
- **T wave** – a record of fast ventricular repolarization
- **U wave** – a record of (most probably) Purkinje's fibres repolarization
- **J point** is also distinguished; it is a junction between QRS complex and ST segment

b/ **segments** – the sections of the ECG between the waves:

- **PQ (PR!) segment** – it begins with the end of the P wave and ends with the onset of the QRS complex, represents the onset of atrial repolarization and electrical impulses conduction from atria to ventricles, through atrio-ventricular node, the bundle of His and Purkinje network;
- **ST segment** - begins with the end of the QRS complex and ends with the onset of the T wave, represents the early part of slow repolarization of ventricles,
- **TP segment** – begins with the end of the T wave and ends with the onset of the following P wave, represents the time during which electrical activity of the heart is absent.

ATTENTION! This TP segment determines the level of isoelectric line (0 mV).

c/ **intervals** – include waves and complexes:

- **PQ (PR!) interval** – it begins with the onset of P wave and ends with the onset of the QRS complex, represents depolarization and the onset of repolarization of the atria and the time of the conduction of impulses from the atria to the ventricles.
- **QT interval** – it begins with the onset of QRS complex and ends with the end of T wave, represents the duration of electrical activity of the ventricles (their depolarization and repolarization).

ATTENTION! It is one of the most important fragments of ECG curve, particularly in the assessment of the risk of sudden cardiac death!

- **RR interval** – it begins with the peak of one R wave and ends with the peak of the succeeding R wave,
- **PP interval** – it begins with the peak of one P wave and ends with the peak of the succeeding P wave. When the heart rate is normal PP and RR intervals are equal and represent one cardiac cycle.

2/. Speed, path and time

A standard paper speed of ECG machines is **25 mm/s** (this value is accepted by the majority of the medical world).

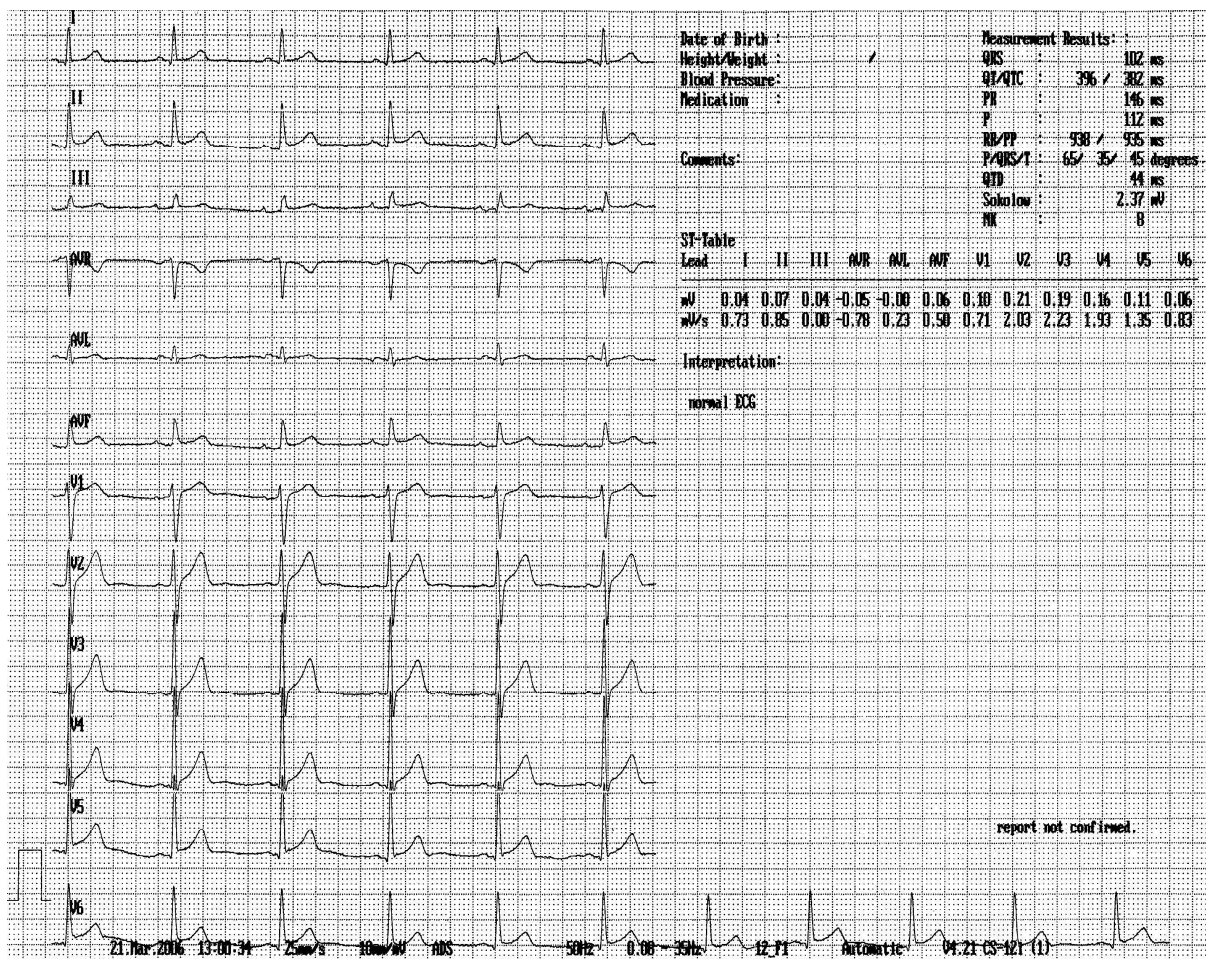


Fig. 9. ECG (speed 25 mm/s)

At this paper speed – within 1 second (1000 ms) 25 mm of ECG paper will be used, and thus 1 mm record corresponds to 40 milliseconds (0,04 s).

In Poland the speed of **50 mm/s** is very frequently used during ECG recording.

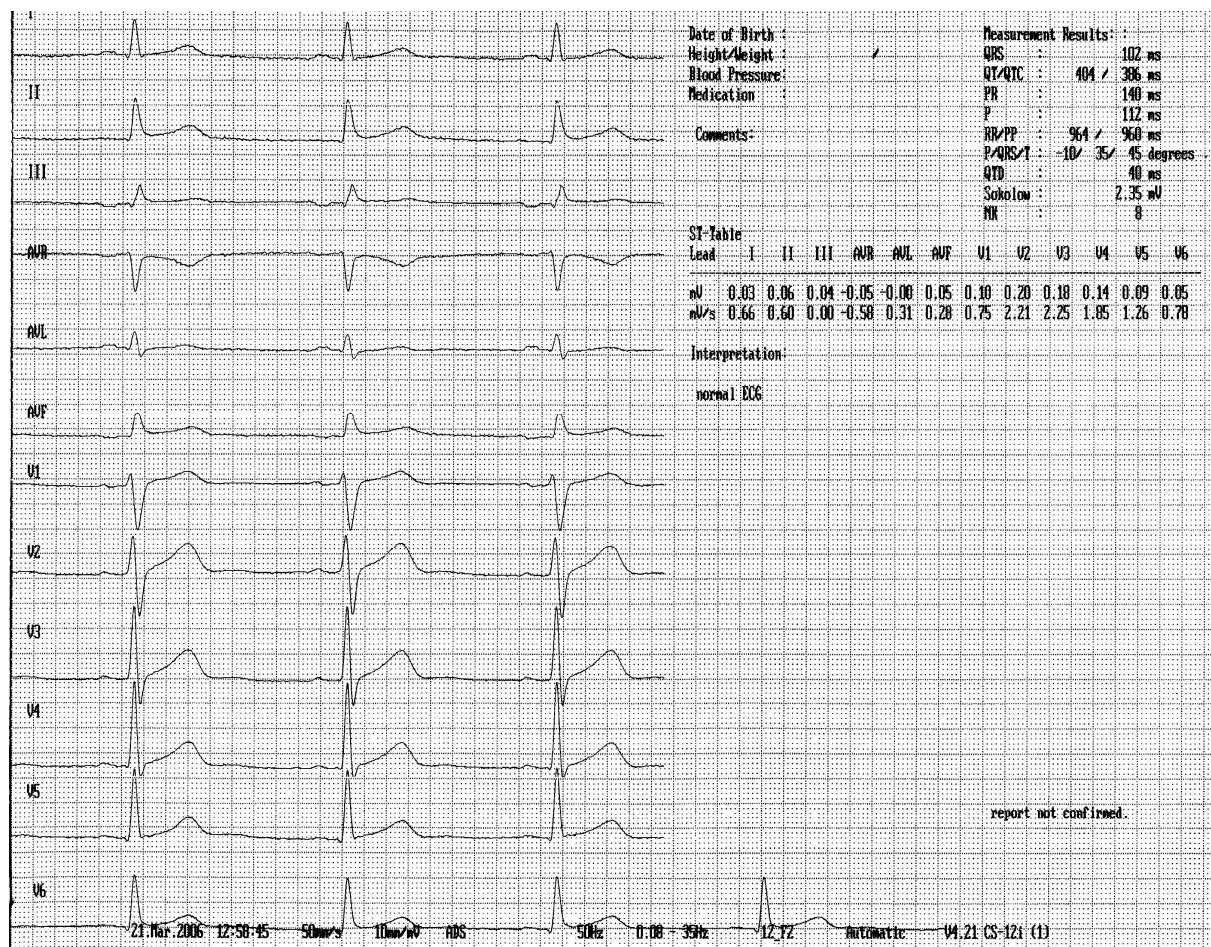


Fig. 10. ECG (speed 50 mm/s)

In such conditions 1 mm record corresponds to 20 milliseconds (0,02 s). At this paper speed a better “legibility” of the recording is obtained.

When the paper speed is known, it is easy to estimate the duration of particular electrical events in the heart and thus the duration of waves, segments and intervals.

3/. Amplitude

On each ECG record there is a test “calibration” signal. The test square wave of 1 mV typically placed at the beginning of the ECG record corresponds to a deflection of 1 cm above the isoelectric line (1 mV = 1 cm). Such calibration signal is needed to properly assess the amplitude of ECG waves.

ATTENTION! In case of not typically calibrated ECG record, the following formula should be used to get the real amplitude of the given ECG wave:

$$\frac{\text{measured wave amplitude}}{(\text{x}) \text{ real wave amplitude}} = \frac{\text{measured calibration signal amplitude}}{\text{normal calibration signal amplitude (10 mm)}}$$

and thus:

$$x = \frac{\text{measured wave amplitude} \times 10}{\text{measured calibration signal amplitude}}$$

4/. ECG standards

It should be remembered that the values of the time of duration and the height of particular ECG components are not constant but different in particular leads in which they are estimated. Usually these measurements are performed in ECG limb lead II (classic)

a/ **height standards (amplitude)** of particular waves:

- P wave – 1-2,5 mm (0,1-0,25 mV)
- Q wave – 0-3 mm (0-0,3 mV)
- R wave – 6-20 mm (0,6-2,0 mV)
- S wave – 0-8 mm (0-0,8 mV)
- T wave – 2,5-6 mm (0,25-0,6 mV)

b/ **duration standards** of waves, segments and intervals:

- P wave - ≤ 110 ms
- QRS complex – 60-90 ms
- PQ (PR) segment – 40-100 ms
- PQ (PR) interval – 110-200 ms (at HR ≤ 90 /min)

- QT interval – max. 360-410 ms(at HR~ 60/min)
min. 280-330 ms (at HR~ 90/min)
- T wave – 120-160 ms

5/ Description of ECG components

a/. **P wave** – represents depolarization of the right and left atrium. Its ascending part reflects depolarization of the right atrium and the descending part of the left atrium.

Normal sinus P wave is always positive in lead III (and V₆) and negative – in lead aVR; the inclination angle of P wave electrical axis in the frontal plane is 0° to +70°.

P waves can be:

tall – they occur in subjects with right atrial hypertrophy (e.g. chronic obstructive pulmonary disease, organic heart diseases), in sympathetic system preponderance, in coronary heart disease and hyperthyroidism

wide (sometimes bifurcated) – in conditions leading to left atrial hypertrophy, e.g. mitral stenosis, mitral regurgitation, arterial hypertension

negative – it is always an abnormal phenomenon and indicates that the stimulus has been originated not in the sinus node but in other pacemaker cells

invisible:

- hidden in QRS complex (e.g. during A-V nodal rhythm or atrio-ventricular nodal re-entry tachycardia – AVNRT)
- periodically buried in QRS complexes or T waves (e.g. in A-V III° block)
- occur in the form of f waves (slight, irregular oscillations of the isoelectric line – during atrial fibrillation) or F waves (tall, occurring regularly – during atrial flutter)

b/ PR (PR) segment and interval

PR (PR) segment represents the onset of repolarization of the atria (which lasts until the onset of ST segment) and the time of progression of the impulse from the AV node through the bundle of His, bundle branches and Purkinje network.

PQ (PR) interval represents the duration of both P wave and PQ segment and thus additionally the time of atrial depolarization

If a detailed endocardiac ECG record is registered (during invasive electrophysiological study) – look at Fig. 11 – 4 subperiods can be distinguished within PQ (PR) interval

- PA segment (0-40 ms) – duration of intra-atrial conduction
- AH segment (<120 ms) - time of atrio-ventricular conduction
- H segment (< 10 ms) – time of conduction in the bundle of His
- HV segment (< 55 ms) - time of intra-ventricular conduction (within Purkinje network)

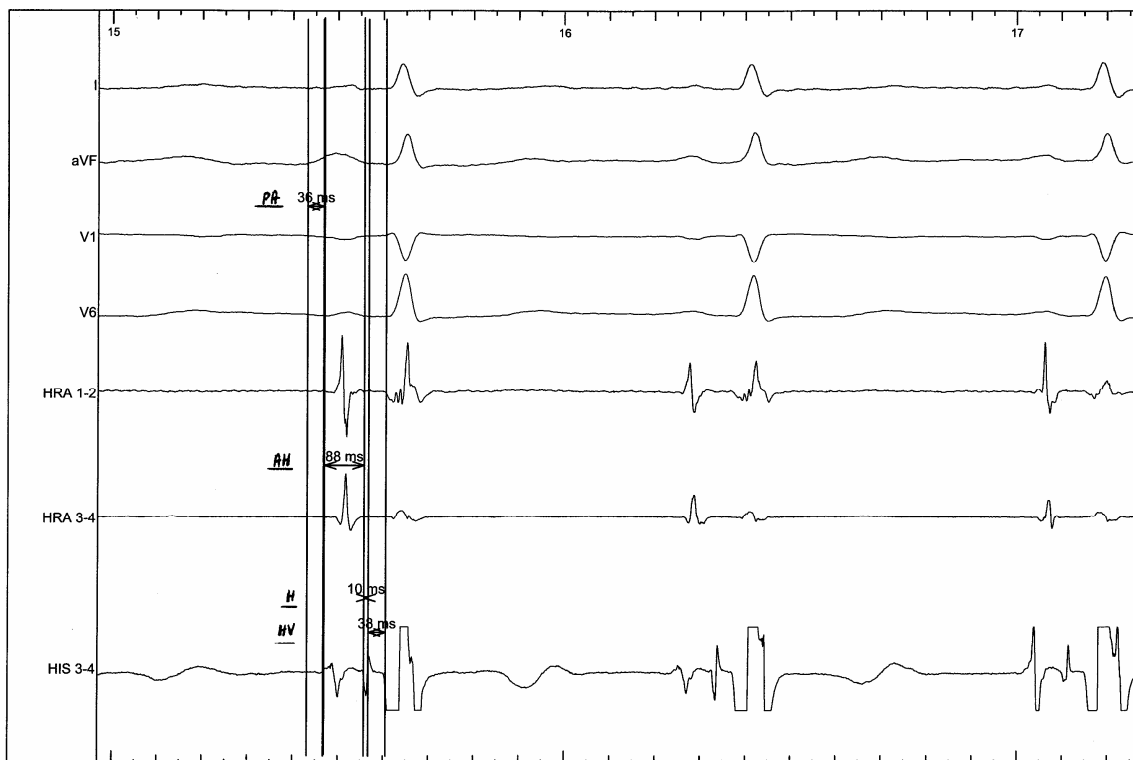


Fig. 11. ECG (I, aVF, V1, V6 and endocardiac leads)

PQ (PR) interval should not exceed 200 ms (at HR \leq 90 min) and be \leq 170 ms in children; in tachycardia $>$ 90/min the PQ (PR) interval upper limit is shortened a little.

The shortening of PQ (PR) interval \leq 110 ms allows easier recognition of atrio-ventricular conduction (e.g. in pre-excitation syndromes).

Prolongation of PQ (PR) interval $>$ 200 ms allows to recognize impaired atrio-ventricular conduction (that is A-V I⁰ block, hidden block!).

ATTENTION!

*-It seems to be more justified to use the name **PR segment / interval** (instead of PQ), because Q wave is often absent and R wave should be present in each lead of normal ECG.*

*-According to many authors the most acceptable upper limit for **PQ/PR interval** is \leq 220ms.*

c/. QRS complex

The QRS complex, which is called *ventricular* represents depolarization of the right and left ventricles. The QRS complex nomenclature requires detailed explanation:

- each positive upright deflection is called R wave; there may be several of these (the second positive deflection in the ventricular complex is called R prime (R') and so forth)

- the first (before R wave) negative deflection starting the ventricular complex is called the Q wave and is present in leads: I, aV1 and V₅-V₆

- each next (following R wave) negative deflection in ventricular complex is called S wave (there may be several of these). Subsequent negative deflection after R wave is called S prime (S') and so forth

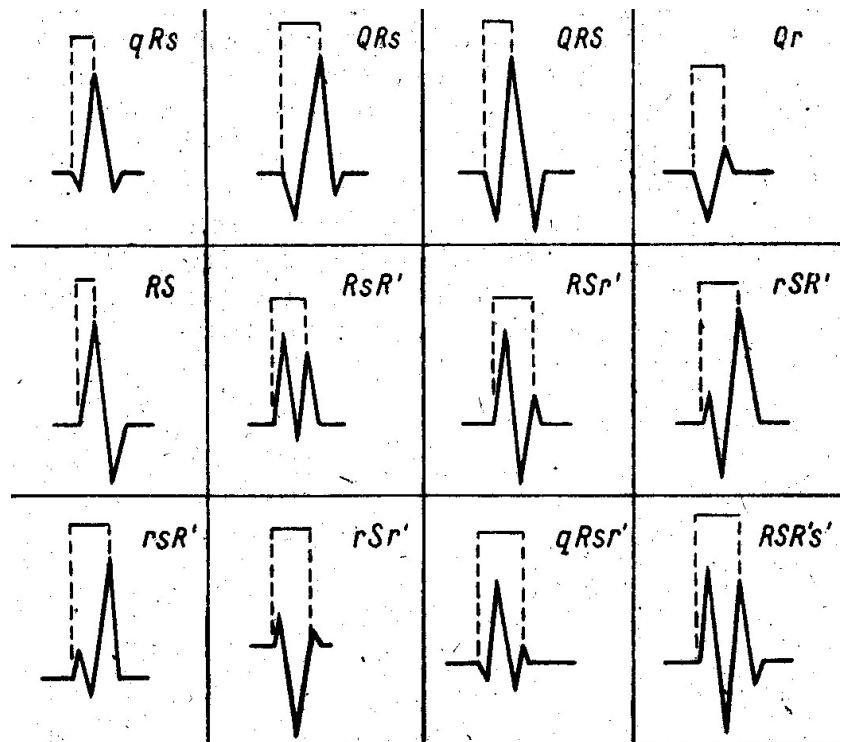
- if the ventricular complex (QRS) does not have negative deflections at all, it is called type R complex; if there is no positive deflection – it is called QS complex (e.g. healed infarct).

- small waves (with low amplitude) in the ventricular complex are identified by lower case letters (q, r, s)

- large waves (of high amplitude) in the ventricular complex are identified by upper case letters (Q, R, S)

Exemplary descriptions of various shapes of QRS complexes are presented in fig. 12

Fig. 12
Examples of QRS complexes



If the sum of positive (R) and negative (Q, s) waves is positive – the QRS complex is *positive*

(upright); if the sum is negative – the QRS complex is *inverted*; if the sum of positive and negative deflections is equal – this is an *equiphasic* complex (partly positive, partly negative)

In precordial leads ($V_1 - V_6$) a characteristic progression from inverted to positive complexes is observed and thus gradual progression of R waves and regression of S waves is observed. Levelling of the amplitude of S and R waves is usually found between the position of the electrode V_3 and V_4 .

Increase in the amplitude of R waves in limb and left-ventricular leads – is observed in, e.g. left-ventricular hypertrophy and in the case of abnormal conduction within the left branch of bundle of His. Increase in R wave amplitude in right-ventricular precordial leads occurs, e.g. in right-ventricular hypertrophy, in posterior or posterolateral myocardial infarction, in impaired conduction within the right branch of bundle of His.

Small narrow Q wave ($\leq 0,03$ s) is present in the majority of leads: it should always be present in the leads: I, aVL, V_5 , V_6 , whereas its presence in V_2 - V_3 leads is abnormal. Thus, Q wave is considered to be pathological if it is observed in V_2 - V_3 leads and if it lasts > 30 ms (0,03 s) in the remaining leads.

ATTENTION!

- The presence of deep Q wave and short R wave in lead III may depend on high positioning of the diaphragm, that is why in the case of diagnostic doubts ECG should always be recorded at the pick of inspiration; if these were due to changes in position, then during deep inspiration the amplitude of Q wave will decrease (or Q wave will disappear) and of R wave – will increase.
- A notch on the ascending arm of R wave, the so called **delta wave** represents the preexcitation syndrome and indicates depolarization of part of the ventricular muscle through an additional atrioventricular pathway (Kent's bundle, Mahaim's fibres).
- While analysing the QRS complex, **ventricular activation time** is also estimated, i.e. a **negative vector** or **intrinsicoid deflection**. It is the time from the onset of the QRS complex to the peak of the R wave (fig.13).

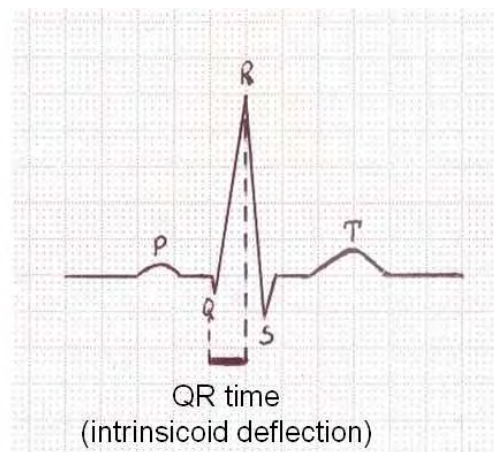


Fig. 13. Determination of the negative vector

This negative vector is an exponent of the conduction rate and the thickness of myocardium; it is different for the right (≤ 35 ms) and left (≤ 45 ms) ventricles. Prolongation of ventricular activation time is useful in diagnosing branch blocks as well as myocardial hypertrophy.

d/. Junction point J

The name originates from English and means the junction between the QRS complex and the ST segment. In normal ECG, the J point should be on the isoelectric line (maximum 1 mm above or below this line).

***ATTENTION!** Higher deviation of the J point in precordial leads (sometimes also in limb leads) with accompanying concave elevations of ST segment in these leads may be observed in healthy subjects and is called premature ventricular repolarization syndrome. It can lead to diagnostic mistakes and “over-diagnosis” of myocardial infarctions (STEMI – ST elevation myocardial infarction).*

e/. ST segment

The ST segment represents early (slow) phase of repolarization of the right and left ventricles. In normal ECG records, ST segment is flat (isoelectric – max. – 0,5 depression, + 1 mm elevation); leads V₁-V₃ are an exception – where ST segment elevation can reach 2 mm.

ST segment appearance can vary:

- horizontally in isoelectric line (STANDARD!)
- horizontal depression of ST segment (typical for myocardial ischaemia)
- down sloping depression of ST segment (typical for myocardial ischaemia and overloading of the given ventricle)
- slanting upwards depression of ST segment (may be the variant of the standard)
- slagging depression of ST segment (over dosage of digitalis)
- concave upwards elevation of ST segment (typical for premature ventricular repolarisation syndrome)
- ST segment elevation, convex upwards (Pardee’s wave – characteristic in STEMI)

The assessment of the ST segment is particularly important in the analysis of myocardial ischaemia; due to common prevalence of ischaemic heart disease and its share in morbidity and mortality in the Polish population, various ST segment appearance in this pathology is presented in fig. 14.

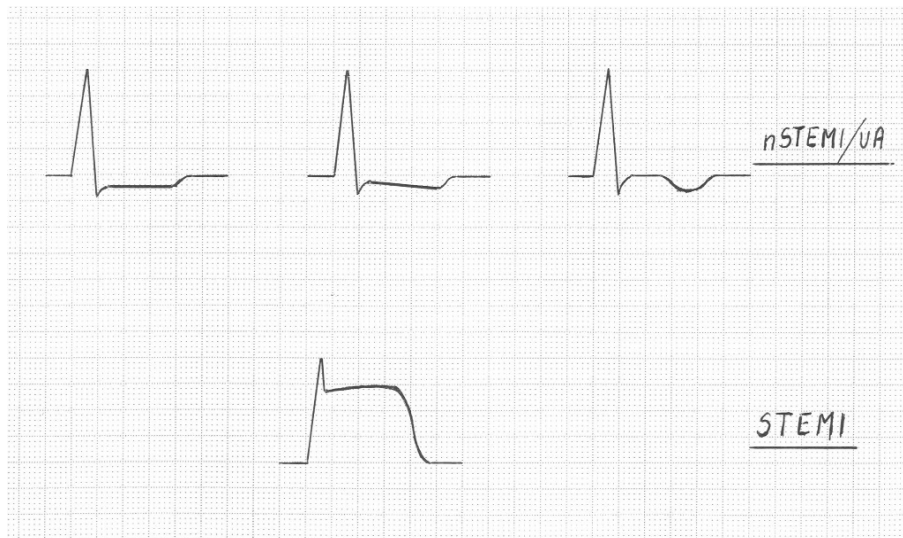

Fig. 14 The shape of ST-T complexes in ischaemia

f/. T wave

T wave represents the final (abrupt) phase of ventricular repolarization. In majority of leads the T wave is positive (deflected above the isoelectric line), negative in aVR lead (and often in V₁, flat or shallow – negative in III, aVF, less frequently in a VI lead.

Other variations of this shaping that particularly occur in pathological conditions are:

- T wave flat (isoelectric) in physiological conditions found in leads: III, aVF, aVL
- T wave negative – in physiological conditions found in aVR lead and often in lead V₁; in pathological conditions it is typical of coronary heart disease
- T wave two-humped
- T wave biphasic (usually - +)
- T wave sharply peaked, tall (characteristically in acute coronary heart disease and hyperkalemia)

- secondary changes of T wave (abnormal repolarization resulting from artificial stimulation, disorders in intraventricular conduction or the presence of additional atrium-ventricular pathway)
- alternating T waves

ATTENTION!

Positive T wave in aVR lead is an abnormality (e.g. it is observed in extensive anterior or anterolateral myocardial infarction).

g/. U wave

This wave probably represents Purkinje cells repolarization; according to other authors it is an expression of papillary muscles potential (during blood inflow).

U wave is not always present in ECG and is best visible in leads V₂-V₆. Usually, it is positive and its amplitude does not exceed 3 mm.

h/. QT interval

The QT interval is the sum of the time of QRS complex, ST segment and T wave duration.

The time of its duration outstandingly depends on heart rate and thus the determination of its absolute value may be burdened with an error; the slower the heart rate is the longer the QT interval and vice versa – the faster the heart rate the shorter the QT interval.

Hegglin and Holzmann formula is one of the ways to calculate QT interval:

$$QT = 0,39 \times \sqrt{RR} (\pm 0,04 \text{ s})$$

The QT interval is slightly longer in women, in adults and in the sympathetic nervous system preponderance. Frequently the following determinations are performed:

- **corrected QT interval (QTc)** – acc. to Bazett's correction

$$QTc = \frac{QT(\text{ms})}{\sqrt{\frac{60}{HR}}}$$

- **QT interval**

dispersion – that is the

difference between minimum and maximum value of QT interval in 12 ECG leads

An abnormally prolonged QT interval is a very disturbing electrocardiographic phenomenon because it can suggest the occurrence of dangerous ventricular dysfunction (VT/VF), which results from “R on T phenomenon” [an extra systole targeting at the region of T wave peak, that is at the vulnerable phase; may be a trigger of the heart “electric storm”]

Many factors can prolong QT interval:

- physical exercise
- myocardial ischaemia
- hypokalemia, hypomagnesemia, hypocalcemia
- alkalosis
- hypothermia
- drugs (antiarrhythmic! – particularly gr IA and III, macrolide antibiotics, antihistamines, antidepressants and other)
- congenital long QT syndromes (LQTS- resulting from the pathology of potassium channels or sodium cardiomyocytes)

6. Frequency – heart rate

The heart rate expresses the number of myocardial contractions per minute.

To calculate heart rate, a certain mathematical effort should be undertaken. So (fig.15):

- firstly – look thoroughly at the ECG, that is at the graph paper; the smallest squares have the sides of 1 mm length and then bigger grids are formed out of them of 5 mm length [horizontal and vertical lines, i.e. 200 ms, because at the paper speed 25 mm/s → 1 mm = 40 ms.]

- secondly – if we want to know the number of heart beats per min, the number of such 5 mm paper grids coming out within each minute must be counted:

- 1 grid (a’ 5 mm) comes out within 0,2 s
- 5 grids (a’ 5mm) will come out within 1 s

- 300 grids (a' 5 mm) will come out within 1 min ($300 \times 0,2 \text{ s} = 60 \text{ s} = 1 \text{ min}$)
- thirdly – the number of these 300 grids divided by the number of 5 mm grids between the successive RR waves gives the heart rate.

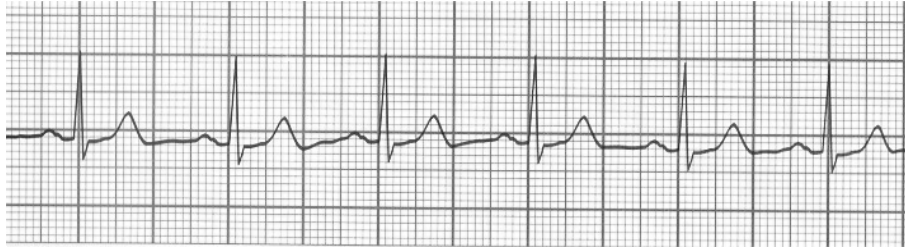


Fig. 15. The record of ECG (Lead II)

$$\text{Heart rate} = 300/\text{min}: 4 = 75/\text{min}$$

Of course, at the paper speed of 50 mm/s – because here 600 grids of 5 mm side is printed within one minute – to calculate heart rate, 600 should be inserted into the numerator of the above formula and it should be divided by the number of 5 mm grids between the successive R waves.

Another way of calculating the rate is to divide the time unit by the length of a single cardiac cycle (RR interval). Considering the same example, 60 s (i.e. 1 min) should be divided by 0,8 s (4 grids of 5 mm side = 20 grids of the side of 1 mm = $20 \times 40 \text{ ms} = 800 \text{ ms} = 0,8 \text{ s}$).

$$\text{Heart rate} = \frac{60}{0,8 \text{ s}} = 75 / \text{min}$$

If (in this ECG) 1 evolution lasts 0,8 s and in 60 s there will be 75 cycles/min then in 1 s:

1: 0,8 = 1,25 cycles per second (that is 1,25 Hz).

In everyday practice, a special cardiologic scale (fig.16) is used, which demonstrates the heart rate with satisfying precision [based on the distance between a few (2-6) successive RR intervals].




Fig. 16. A photograph of a scale

The last remark!

While estimating irregular rhythm (e.g. during atrial fibrillation) the minimum, maximum and mean values must be given.

7/. Cardiac electric axis and its determination

The heart is a peculiar generator of current, which is associated with the creation of the electric field. The electric field is spatial and thus its description using a vector requires a three-dimensional co-ordinate system. Mean vector of the ventricular system (QRS complex) is the resultant of the activation vectors of the interventricular septum, cardiac apex, inferior wall and free RV and LV walls (these in turn are the resultants of local summation vectors).

However, in everyday practice, the projection of QRS complex vector on the frontal plane supplies sufficient information; thus when we speak about cardiac electrical axis we actually speak about its component in the frontal plane.

In clinical practice, cardiac electrical axis can be determined in different ways:

- the system of typical QRS deflections in leads I, II and III can be useful for characterizing particular intervals of the axis
- based on the Einthoven's triangle (fig. 17)

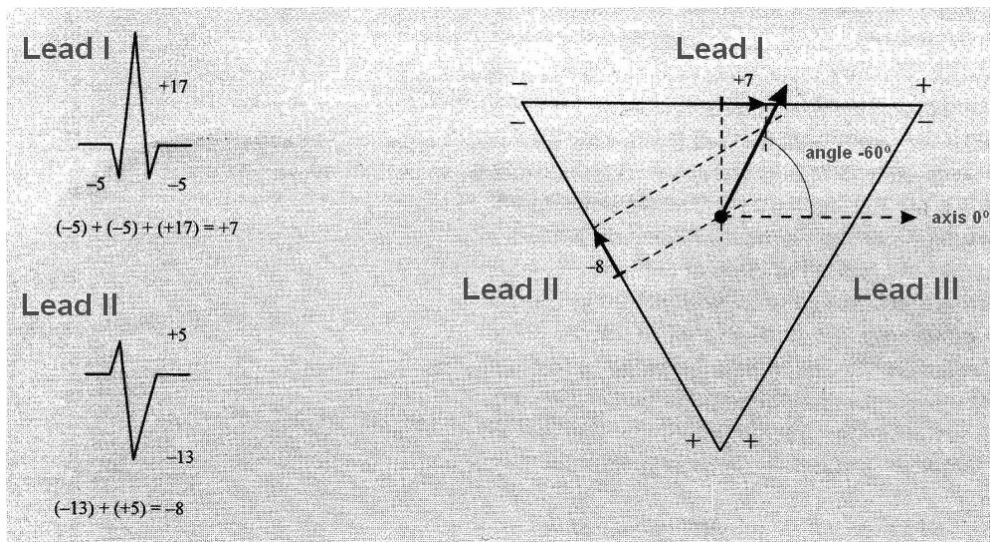


Fig. 17. Einthoven's triangle

This triangle is oriented in the space in such a way that its sides run the axis of classic leads: I (0^0), II ($=60^0$), III ($+120^0$). The signs (+ and -) are marked on this triangle and point zero of the lead axis (in the middle of each side). To determine the direction of the straight line two points are always needed and thus the same number of classic leads is necessary to determine cardiac electric axis. Most frequently leads II and III are chosen. Then, the values of R waves (positive) and Q and S waves (negative) are summed. Next, the calculated values from the middle point of lead axes I and III are shifted into the proper direction (preserving the signs + and -). Finally, perpendicular lines are drawn through the ends of segments marked on the triangle sides and the points of their crossing determine the mean vector of QRS complex axis.

- based on the circle of Carbera (1st way) (fig. 18)

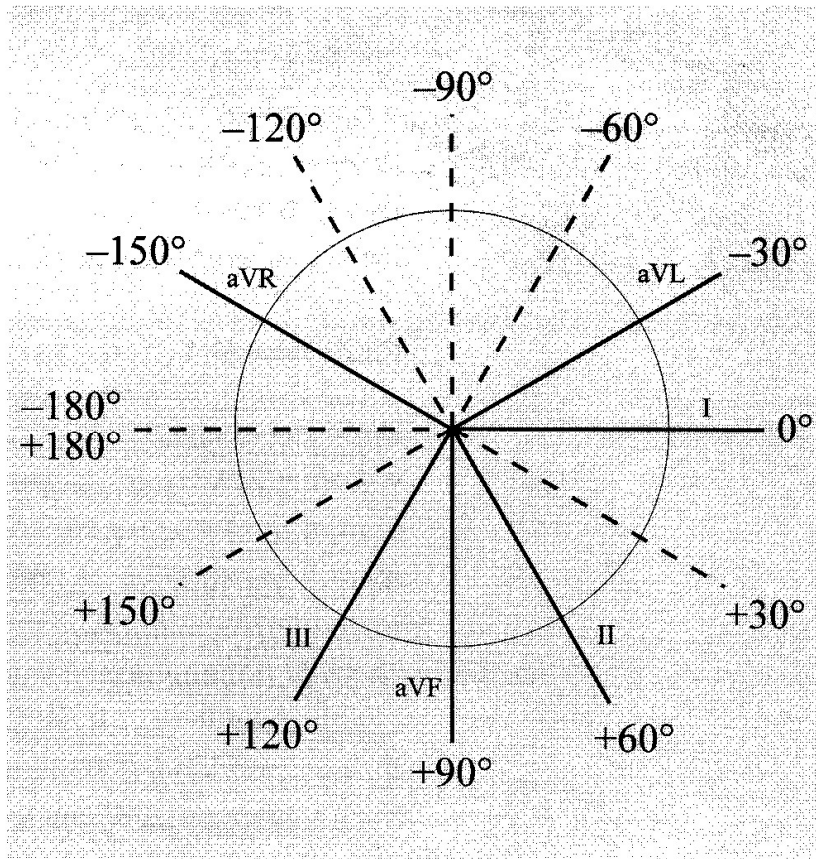


Fig. 18 The circle of Cabrera

It should be remembered that the cardiac axis is (approximately) parallel to the axis of the lead in which main deflection of QRS complex is the biggest; only the absolute value of this deflection is considered. Precision of this method is not high. Most frequently, determination of the range of values in which the cardiac axis is included, is a success.

- based on the circle of Cabrera (2nd way)

Remember that the cardiac axis is perpendicular to the axis of the lead in which the sum of positive and negative deflections equals zero (or is close to zero).

In healthy subjects the direction of the cardiac electrical axis is in the range from 0° to $+90^{\circ}$ (**normal QRS axis**). If the electrical axis is in the range from $+90^{\circ}$ to $+180^{\circ}$, it is called **right axis deviation**; when the electrical axis is in the range from 0° to -90° it is called **left**

axis deviation. However, if the electrical axis is in the range from -90° to $+180^{\circ}$ – it is called **indeterminate electrical axis**

Figure 19 shows a system of limb leads in frontal plane with the presentation of angle values and 4 ranges of the axis – normal QRS axis, left axis deviation, right axis deviation and indeterminate axis.

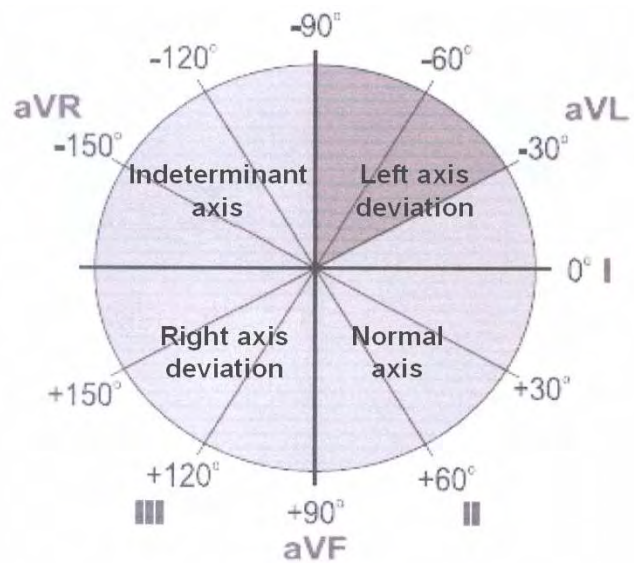


Fig. 19. Presentation of the axis of limb leads system

- the electrical axis can be determined using leads I and aVF, which are perpendicular to each other. Each axis from the particular leads has positive or negative field. The positive field of lead I is in the range from $+90^{\circ}$ to -90° – right half of the circle. The negative field – the left half of the circle, ranges from -90° to $+90^{\circ}$. The positive field for aVF lead forms the lower half of the circle and the negative field – the upper half. Thus, while assessing QRS complex deflections in these two leads, it will be possible to determine in which part (quadrant) of the circle the cardiac electrical axis is. If the predominant deflection of QRS complex in lead I is positive – then (see fig. 20) the axis is in the range from normal to left axis deviation, that is from $+90^{\circ}$ to -90° . If, simultaneously, the dominating deflection of QRS complex in aVF lead is positive, then the cardiac electrical axis is in the range from 0° to $+90^{\circ}$ – normal QRS axis. If QRS complex is positive in lead I and the negative phase is predominant in lead aVF – the cardiac axis is included in the range from 0° to -90° – it is left axis deviation. It also should be decided whether it is pathological (range from -30° to -90°) or not. This can be settled looking at lead II: if QRS complex is positive – the axis is in the range 0° – 30° – left axis deviation. If QRS complex in lead II is negative – it is the pathological left axis deviation. If however, QRS complex in lead I is negative, the cardiac axis is in the range of right axis deviation and indeterminate axis. The indeterminate axis (-90° to -180°) will be recognized when simultaneously, QRS complex is negative in aVF lead. If

QRS complex in aVF lead is positive, the cardiac axis will be in the range of right axis deviation ($+90^{\circ}$ to $+180^{\circ}$).

- in modern ECG equipment, the values of axes, P waves, QRS complexes and T waves are calculated on the record.

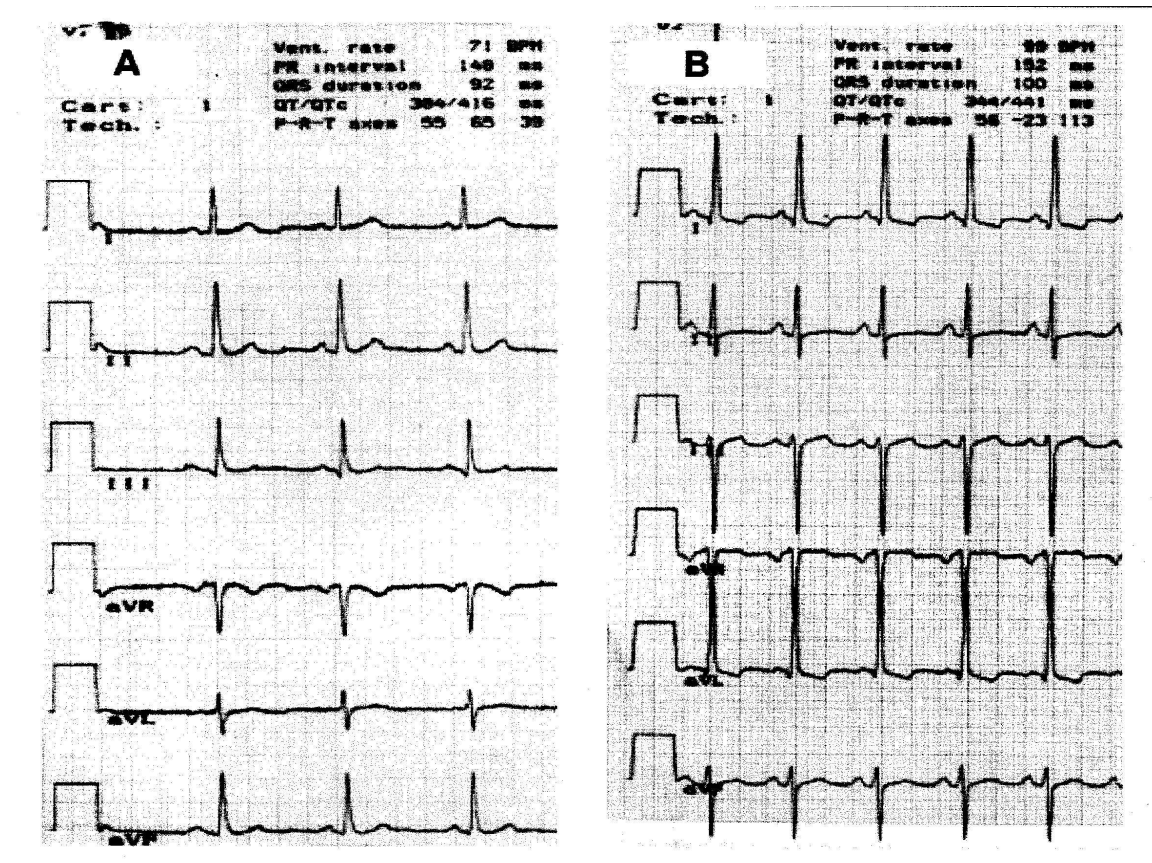


Fig. 20. Examples of QRS axis: A – normal axis B – left axis deviation

Fig. 20: record 2A – lead I – QRS complex is positive, lead aVF – also positive – cardiac axis in the range from 0° to $+90^{\circ}$, that is **normal QRS axis**, precisely $+65^{\circ}$ (as calculated by a program in ECG apparatus).

record 2B: lead I – QRS complex is positive and aVF – negative – this means that the cardiac axis is in the range from 0° to -90° , thus in the range of **left axis deviation**; it must be determined whether it is a pathological left axis deviation; cardiac axis is positive, in the range from 0° to -30° , when QRS complex is positive in lead II – the axis is recorded as “left axis deviation” without an adjective pathological (as calculated by a program in ECG apparatus: -23°)

ATTENTION! Determination of electrical axis is made easier by the following observation:

- *if the predominant QRS complex deflections in leads I and III are directed to each other – it is a right axis deviation,*
- *if the predominant QRS complex deflections in leads I and III are directed apart, the electrical axis is deviated to the left.*

Interpretation of cardiac electrical axis deviation

- **in healthy subjects** the electric axis deviation is in the range from 0° to $+90^{\circ}$
- **left axis deviation** (QRS complexes shaped divergently – “apart”) can be observed: when the diaphragm is positioned high (e.g. in pregnant or obese subjects), in left ventricular hypertrophy (e.g. in arterial hypertension, in organic heart diseases leading to left ventricular hypertrophy, in primary hypertrophic cardiomyopathy) and abnormal intraventricular conduction (block of the left branch of the bundle of His, left ventricular block)
- **right axis deviation** (QRS complexes in leads I and III are directed to each other – deep S waves in lead I and tall R waves in lead III) occurs: when the diaphragm is positioned low (in tall, slim subjects), in right ventricular hypertrophy (in chronic cor pulmonale, in organic heart diseases burdening right ventricle, acute cor pulmonale (eg. pulmonary embolism) and in anomalous intraventricular conduction (right branch block of the bundle of His, left posterior fascicular block)

Estimation of heart position in chest

While assessing cardiac electrical axis, it should be remembered that it is not anatomical position of the heart in relation to chest walls that is being described, but the course of a minute QRS vector. However, in the heart of healthy subjects the direction of the vector is similar to the long anatomical axis; thus on the basis of QRS complexes shape (if other factors are not considered, e.g. left ventricular hypertrophy or left branch block of the bundle of His) the position of the heart in the chest may be indirectly concluded.

The estimation of heart position in chest may be carried out on the basis of the shape of dominating QRS complexes deflections in leads aVL and aVF (the picture of QRS complexes is similar to QRS complexes in leads I and III).

In vertical position – in aVL lead, a deep S wave is predominant and in aVF lead is similar to QRS complex in V₁ or V₂ lead and in aVF – to V₅-V₆.

In semivertical position – in aVL lead QRS complex has low amplitude and in aVF lead – tall R wave (QRS complex is similar to QRS complex in lead V₅-V₆)

In horizontal position – in aVL lead, a tall R wave is predominant and in aVF lead – deep S wave (QRS complex in aVL lead is similar to QRS complex in lead V₅ or V₆, while in aVF lead – to V₁ or V₂)

In semi horizontal position – in aVL lead, a tall R wave is predominant and in aVF lead – QRS complex has low amplitude (QRS complex in aVL lead is similar to QRS complex in V₅ or V₆)

In indirect or oblique position – both in aVL and aVF leads QRS complexes are positive and similar to those in leads V₅, V₆.

Changes of heart position round its long axis – rotations

These are determined in precordial leads on the basis of the R and S waves ratio. Usually in precordial leads V₃ and V₄ R wave appears to be equal to S wave.

- the shift of “rightventricular” picture more to the right in the band of precordial leads (deep S wave up to V₅, V₆) proves the rotation of heart anatomical axis to the right – dextrogyration
- the shift of “leftventricular” picture to the left (tall R wave also in V₁-V₂ – proves the rotation of heart anatomical long axis to the left – sinistrogyration
- when the apex of the heart is close to the front – deeper Q waves are observed in all limb bipolar leads
- when the apex of the heart is displaced backward – the presence of deep S wave is observed in all limb bipolar leads.

VI/. Equipment and conditions of normal ECG record

Modern ECG machines use the latest achievements of electronic engineering and electrical engineering – they are peculiar computers capable of recording and processing huge amount of data. An example of a currently used ECG device is presented in fig. 21.



Fig.21. ECG recording device

Recording an ECG

The ECG should be performed in the conditions, which guarantee the best quality of the recording. The room should be protected with a special screen (Faraday cage) against electromagnetic interference. A bed should be comfortable, long and wide enough for the patient.

To decrease electrical resistance between the patient's skin and the electrodes – electrode jelly is rubbed into the skin under the plates. These places can also be moistened with gauze pads with 0,9% NaCl or water.

Having been attached to proper places on the chest surface and on limbs, the electrodes are connected to the plugs and cables according to colour labelling.

During ECG recording:

- the patient should stay relaxed, the muscles must not be tense and he/she should breath quietly
- sometimes the ECG record is performed from particular leads on the peak of deep inspiration, when the heart changes its position in the chest, the tension of the vagus nerve decreases (particularly when negative T and Q waves are registered in leads II, III and aVF then this picture should be verified on inspiration)
- two basic paper speeds are used – 25 mm/s (commonly accepted standard) and 50 mm/s.

The most frequent causes of abnormal ECG curves (artefacts) are as follows:

- muscle tremor (fig. 22)
- alternating current interference (fig. 23)
- dirty skin
- loose electrodes
- intense breathing movements
- touching metal elements with a hand or a leg
- improper calibration of the ECG machine
- changeable paper speed

ATTENTION!

Wrong attachment of electrodes and changes in colours of cables can be the cause of an improper interpretation of ECG!!!

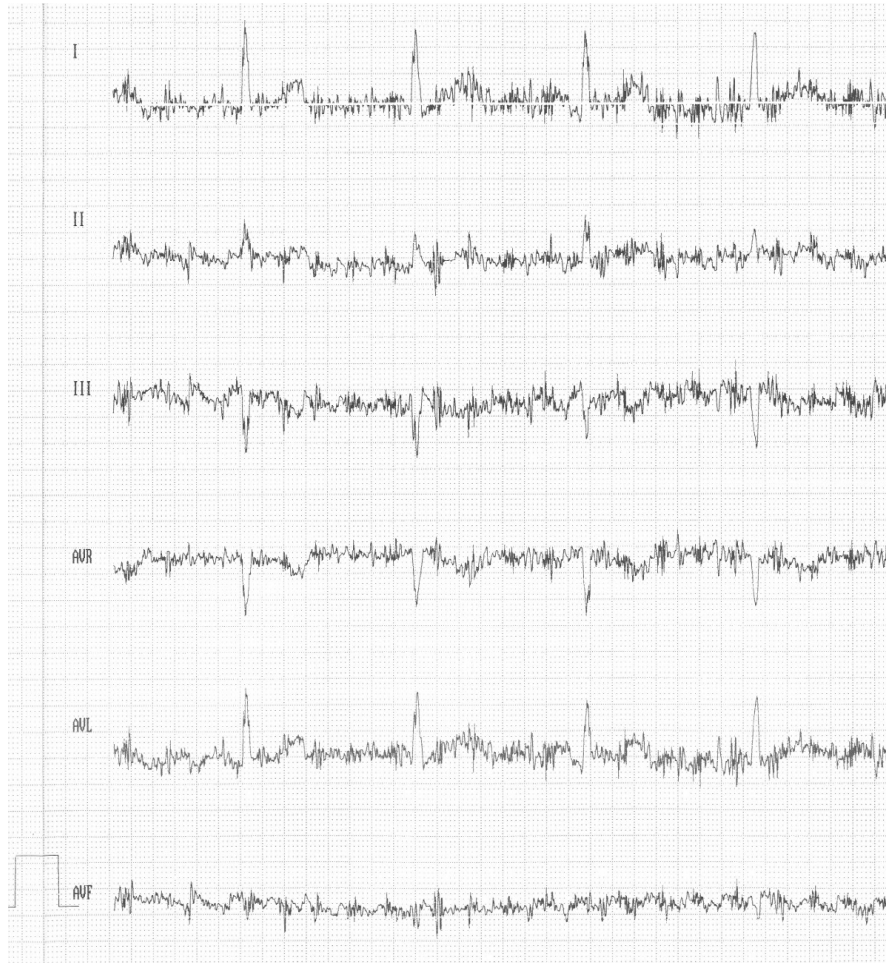


Fig.22 Deformation of ECG curve as a result of muscle tremor

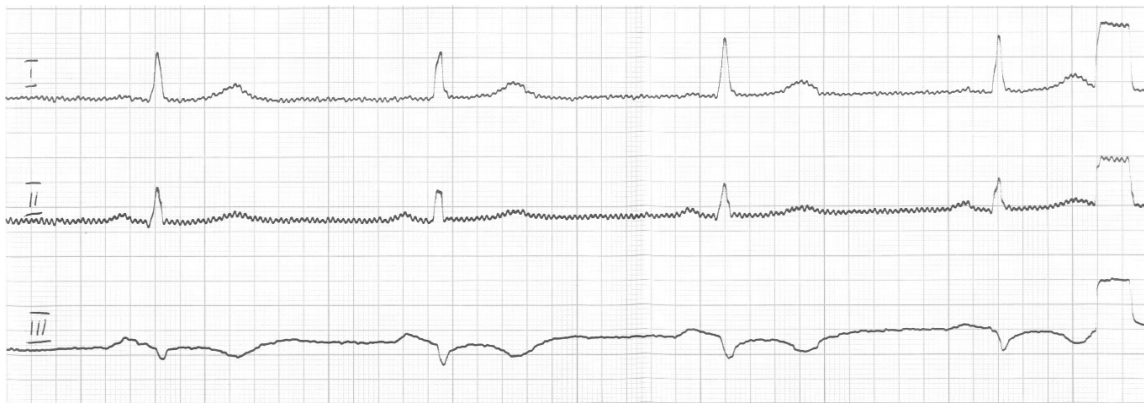

Fig. 23. Deformation of ECG curve as a result of interference of current

VII/. Normal ECG curve

The correct ECG recording is a graphical representation of the bioelectrical currents that are generated by the myocardial cells in healthy subjects (fig. 7)

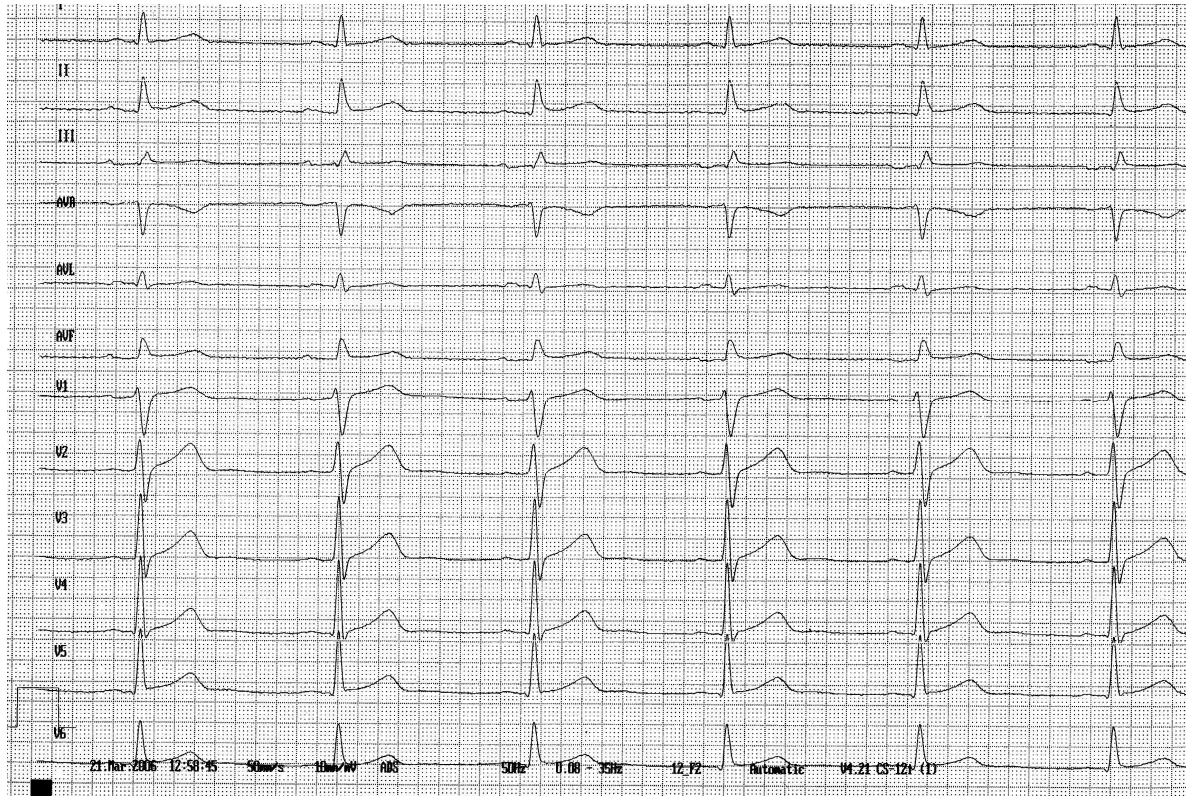

Fig. 7. Normal ECG

Superior peacemaker, that is the sinus node controls physiological electrical function of the heart. If every successive cycle of cardiac performance (including depolarization /repolarization of atria and ventricles) is initiated by the sinus node – **normal cardiac rhythm is called sinus rhythm**

The following criteria must be met to consider the sinus rhythm normal:

1/. P waves – are of the sinus origin if:

- they are positive in leads II and III (and in V₆)
- they are negative in aVR lead

- their electrical axis is within the range from 0° to $+75^{\circ}$ (most frequently from $+30^{\circ}$ to $+60^{\circ}$)

2/. P waves demonstrate a close relation to QRS complexes, that is frequency P = QRS frequency and interval $120 \text{ ms} < \text{PQ (PR)} \leq 200 \text{ ms}$

While analysing each ECG record, strictly determined order of activities should be followed:

- to establish whether P waves are present (and if they are of sinus /extra sinus origin)
- to estimate the association of P waves with QRS complexes and the sequence of ventricular beats
- to determine the heart rate and rhythm, electrical axis and position
- to evaluate ST-T changes
- to name the recorded arrhythmia and conduction disturbances.

Estimation of ECG can be more thorough by presenting Lewis' diagram (fig. 24)

This diagram enables to determine in a clear way:

- pacemaker location
 - course of excitation
- and /or
- conduction block

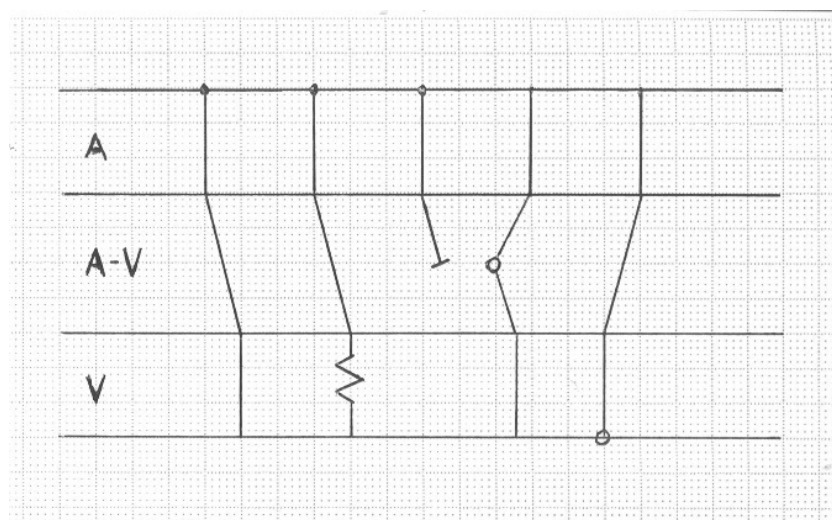


Fig. 25. Lewis diagram

While describing the ECG record from fig. 7, it should be stated:

Regular sinus rhythm of the frequency 62/min with normal atrio-ventricular conduction. Normal QRS axis, heart position indirect. No ST-T changes, without arrhythmia and conduction disturbances.

To end this adventure with electrocardiography, we hope that the future doctors will not have any problems with ECG records!

We also hope that the doctors will always be able to solve even the most complicated electrocardiographic puzzles.

AUTHORS

The procedures at the site of a road accident

A witness to a road accident is obliged to help the victims with the best of his abilities and available resources.

- 1) The witness should stop his vehicle at the site of a road accident, turn on the emergency lights and place the emergency triangle behind the vehicle.
- 2) Secure the crashed vehicle – it poses a danger to the victims and the rescue team; remove the key from the ignition switch, lift the hand brake, extinguish cigarette ends.
- 3) Call paramedics– 'Pogotowie Ratunkowe' (the time of transport to the hospital is crucial for the survival of patients with a hemorrhage).
- 4) Life support should be provided first to the victims with most severe injuries who are unconscious (persons calling loud for help are conscious and apparently can breathe).
- 5) If there is no breathing and no carotid pulse, the victim should be taken out from a vehicle with special attention being paid to a possible injury of the neck spine, by putting our hands under the victim's arms and placing his head over our chest. If a blanket is available, it may be rolled and placed around the neck with the ends crossed over the chest and placed under the armpits.
- 6) Then, the injured subjects must be carried out into a safe place, best if arranged with four persons: one taking care to stabilize the neck, another stabilizing the shoulder girdle, the third – pelvis and the fourth - legs.
- 7) The resuscitation should be started immediately after laying the injured person flat and avoiding raising the head backwards to clear air passage.
- 8) If the injured subject is conscious, he should be carried out of the vehicle as described above and then bleeding control and fracture stabilization should be provided.
- 9) The access to the site of injury should be gained – clothes must be cut off and the evaluation of bleeding type: venous (slow bleeding) or arterial (bright bleeding under pressure) must be performed.
- 10) The wound is to be sealed with a sterile gauze pressure dressing (cotton wool must not be used to cover the wound) and then tied with bandage, which is sealed tighter in case of arterial bleeding; if the dressing soaks with blood, another layer of gauze should be applied

with increased pressure. If the bleeding wound site cannot be wrapped with a pressure dressing i.e. groin, chest surface, neck, it should be held with the rescuer's own hand.

- 11) A broken lower extremity should be stabilized with wrapping one leg with another at the level of the ankle, knee and thigh.
- 12) A broken thigh should be stabilized with a stick or rail reaching from the ankle to above the hip.
- 13) A broken arm is most conveniently bandaged with the forearm being flexed perpendicularly and tied to the chest.
- 14) In case of open fractures the stabilization is not possible and should not be attempted. Fractures and dislocations must not be independently managed.
- 15) In bleeding patients, a plastic cannula of a large diameter should be fixed in a vein while the vessels remain extended.
- 16) First aid kit in car should include:

gloves	sterile gauze
bandages	scissors
sticking plaster	a torch
a plastic cannula	rails

The assessment of essential vital signs

Pulse

Pulse (*pulsus*) is defined as a visible or palpable moving wave of the arterial wall. It is caused by the changes in blood pressure of the volume that is ejected from the left ventricle into the previously extended aorta in a form of wave, which moves along the stream of blood and distally along the arterial walls.

The examination of pulse is performed by palpation using three fingers (from the second to the fourth) along the course of an artery. For optimal conditions, the artery should be pressed against a hard tissue as bone or cartilage. The pulse is palpated usually on the radial, carotid and femoral arteries. The differences on symmetrical arteries, excluding rare inborn anatomical defects, always indicate an abnormality.

Regarding the volume, pulse types are divided into prominent (*pulsus altus*), small (*pulsus parvus*) and filiform (*pulsus filiformis*). The pulse may be markedly tense or hard (*pulsus durus*) or soft (*pulsus mollis*), which is associated with the constriction force of the left ventricle, the volume of blood in circulation and arterial wall resistance. Regarding the velocity of arterial volume load and the rate of its decrease, the pulse is divided into fast (*pulsus celer*) or slow (*pulsus tardus*) type. The pulse can also be described as regular (*pulsus regularis*) or irregular (arrhythmia). Irregularity of pulse in healthy subjects, usually in young persons, may be connected with the breathing cycle and be decreased at the end of expiration.

The normal pulse rate is equal to the heart rate of between 60 to 90 beats per minute. Accelerated pulse rate (tachycardia) is a physiological condition during digestion, physical exercise and increased temperature of the environment. Decreased pulse rate (bradycardia) is common and normal during sleep, in well-trained subjects and occurs in the case of increased vagal nerve tone.

Heart rate

Assessment of heart rate has been discussed in the chapter on chest examination.

Respiratory rate and patterns

The normal respiratory rate is between 12 and 18 cycles per minute. The accelerated respiratory rate is termed tachypnoë, whereas increased - bradypnoë. Definite lack of breathing is termed apnoë. The inspiration phase is slightly shorter than the expiration one and the ratio of these phases is 4:5.

The patterns of respiration include chest and abdominal patterns of breathing. The first, common in women, is associated with rib movements; the other pattern is more typical of men and is connected with the predominant role of the diaphragm.

The normal breathing pattern is regular. The altered, abnormal patterns of breathing include Kussmaul, Biot or Cheyne-Stokes breathing patterns.

The respiration may involve the accessory respiratory muscles or respiratory motion of intercostal spaces, which are considered objective signs of dyspnea (*dyspnoë*). The dyspnea or the feeling of lack of air may cease after assuming erect position, which is a sign of *ortopnoë*.

Arterial blood pressure

The arterial blood pressure (BP) is connected with the force, which is exerted by the blood volume on the walls of the arteries. The level of BP is dependent on two factors: the heart minute ejection volume and the elasticity of arterial walls. Other factors affecting BP include: the volume and viscosity of the blood, body position and emotional state. The BP at the top of pulse wave (due to the constriction of heart ventricles) is called systolic BP, whereas the respective one during the diastole is called diastolic BP. The difference between systolic and diastolic BP is defined as amplitude or pulse pressure. The upper normal level of BP according to World Health Organization is 140/90 mm Hg. Arterial hypertension is diagnosed when the resting BP exceeds 160/95 mm Hg. The values that fall between these two are termed borderline arterial hypertension. Lowered BP is diagnosed if BP is less than 100/60 (in patients under 41) or below 110/65 (after 40). The normal values discussed above are the values of the so-called essential BP, which is measured in the morning, after half an hour rest in a lying position. BP measured in other circumstances is termed as incidental BP.

BP is measured with a sphygmomanometer and there are three types of sphygmomanometers: mercury, clock (string) or electronic with the type specific advantages and disadvantages. Mercury sphygmomanometers are the most reliable type. They include a cuff, rubber connectors with a pump and the measuring device. The width of the cuff is

associated with the diameter of the patient's arm (wider for a thicker arm). The standard width of cuff is 12-15 cm for an adult person, whereas narrower cuffs are used for children.

There are three methods of indirect, non-invasive BP assessment: palpation (Riv-Rocci method and the respective abbreviations of these names – RR, are used to refer to BP), auscultation (Korotkov method) and the oscillatory method, which is rarely used in clinical practice.

The first two methods require using the cuff that is placed on the arm just above the elbow so that the cuff surrounds the skin above the brachial artery. The common errors in measuring BP include misplacement of cuff (metal handle or strip above the artery). The cuff should be placed on the arm with lesser musculature, usually the left. The properly placed cuff is then pumped up under the control of the pulse on the radial artery. The air should be pumped up with extra 20 mm Hg, following the time of pulse disappearance, then slowly released and the systolic value is read out at the time of the appearance of pulse in the methods involving palpation of radial artery. In the method that applies auscultation, the time of pulse disappearance is found using the stethoscope. BP value at the moment of first tone recognition is termed the systolic BP, whereas the value observed at the time of the tone disappearance is termed diastolic BP. The latter cannot be determined with palpation and the method of palpation produces the results that are lower than systolic values by 5-10 mm Hg.

Basic Life Support

European Resuscitation Council 2005

Basic Life Support means saving lives by maintaining airway, supplying ventilation (rescue breathing by blowing air to the victim's mouth) and supplying circulation (external cardiac massage – chest compressions) performed without additional equipment. It is the first step in cardio-pulmonary resuscitation (CPR) that should be initiated by bystanders and continued until qualified help arrives. Next step is Advanced Life Support (ALS), which is performed by medical services.

People with cardiac arrest (CA) need immediate CPR. First aid means BLS that is started by witnesses before the emergency service arrival and is the key action in achieving patient survival.

Basic Life Support sequence:

PATIENT UNRESPONSIVE

Call for help

Open the airway

NO EFFECTIVE BREATHING

Call 112 (can be 999 in Poland)

Perform 30 chest compressions

Continue the sequence:

2 rescue breaths, 30 chest compressions

Detailed BLS scheme:

1. Ensure the safety of the rescuer, victim and witnesses.
2. Check if the victim is responsive: shake victim's shoulders and shout.
3. A/ Yes: leave the victim without changing position; assess regularly.
B/ No: call for help; position supine, open the airway (tilt the head gently by pressing the forehead and lift the chin).
4. After opening the airway assess effective breathing (look for chest and upper abdomen movements, hear for breath sounds, feel for expired air). The assessment must not take more than 10 seconds.
5. A/ The victim is breathing effectively: use recovery position; go or send somebody for help. B/ The victim is not breathing effectively: go or send somebody for help; come back and initiate chest compressions (kneel beside the victim, position your wrist in the middle of the sternum, place the second wrist on the first one and depress sternum 4-5 cm at a rate of 100 per minute while keeping your shoulders straight).
6. Alternate chest compressions (30) with rescue breaths (2) (to give breaths open the airway – tilt the head gently, lift the chin, occlude the nose with the hand pressing the forehead, ensure a good mouth to mouth seal and blow steadily about 500 ml of air within 1 second).
7. Continue BLS until: A/ the victim shows signs of life, B/ qualified help arrives, C/ you are exhausted.

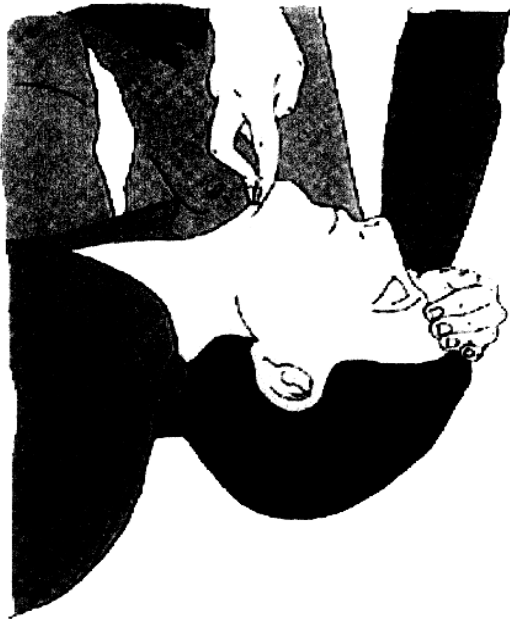REMARKS

1. Airway occlusion despite of the opening maneuvers (tilting head and lifting chin) is usually associated with foreign body in the pharynx, larynx or the trachea (Foreign Body Airway Obstruction - FBAO). The most common cause is food (meat). Partial obstruction when victim is able to speak, breath and cough demands no help. Total obstruction demands immediate rescue action: A/ conscious victim - hit between scapulae with the wrist (5 times) if not effective use compressions of upper abdomen (with the fist between umbilicus and xyphoid process, the second hand placed on the first one, standing behind the victim and pushing up in direction to the heart -

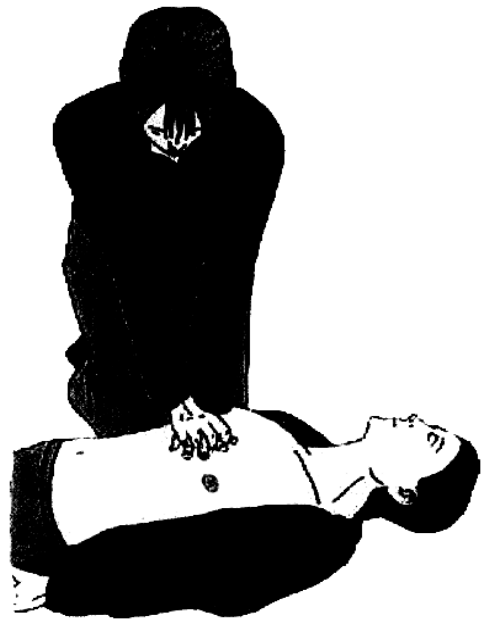Heimlich`s maneuver); B/ unconscious victim – supine position and BLS are necessary. Do not sweep the oral cavity when no foreign bodies are visible.

2. Compressions only CPR. Because some rescuers are reluctant to perform mouth-to-mouth ventilation (especially when unknown victims) it is worth finding out that compressions alone may be equally effective in the first minutes after CA in adults (in cases when asphyxia is not the cause of CA). It is important to know that compressions only CPR is better than no CPR, especially when it is combined with airway patency, which offers some air exchange.
3. CA in asphyxia. This mechanism of CA concerns victims of trauma, poisoning, drowning and children. Modification of BLS consists of: A/ performing 5 rescue breaths before chest compressions; B/ going on with BLS for one minute before calling help.
4. CA in children. Many potential rescuers do not help children because of fear to hurt them. To simplify CPR education, one must realize that adult BLS scheme is much better than doing nothing and a rescuer, who is not trained in Pediatric BLS may use the adult BLS sequence.
5. Signs of agony, very weak or rare breaths are NOT CORRECT, EFFECTIVE BREATHING.
6. DO NOT PRACTICE Esmarch`s maneuver, precordial hit and checking carotid pulse during BLS.
7. Recovery position. ERC guidelines: a/ take the victim`s glasses off, b/ kneel down beside the victim, make sure the victim`s legs are straight, c/ put the victim`s hand at your side up on the square (shoulder and elbow), d/ put the opposite hand across the chest and touch the cheek at your side with its back, e/ take the opposite knee and flex it with your second hand, f/ keeping the hand pushed to the cheek, pull the opposite leg to yourself in a way to turn the victim to your side, g/ lay the leg you pulled before, to place the knee on the square with the hip, h/ tilt the victim`s head to ensure airway patency, i/ if necessary put the victim`s hand under the cheek to maintain head tilted, j/ **assess breathing regularly!**

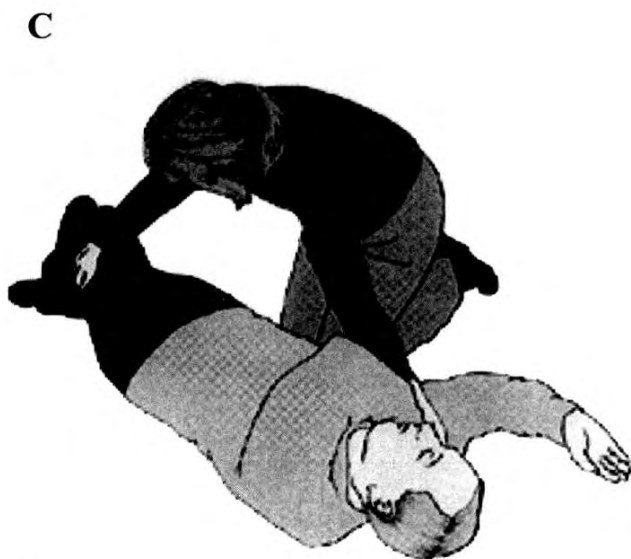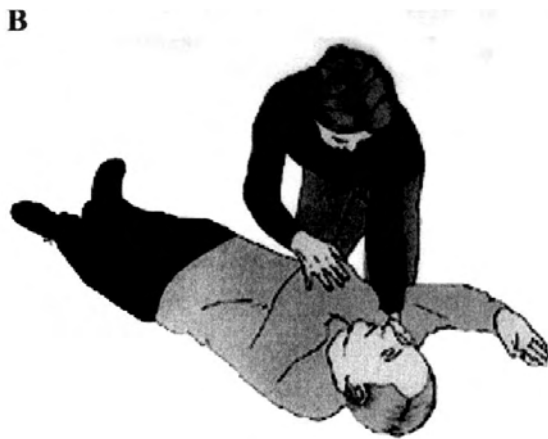FIGURES

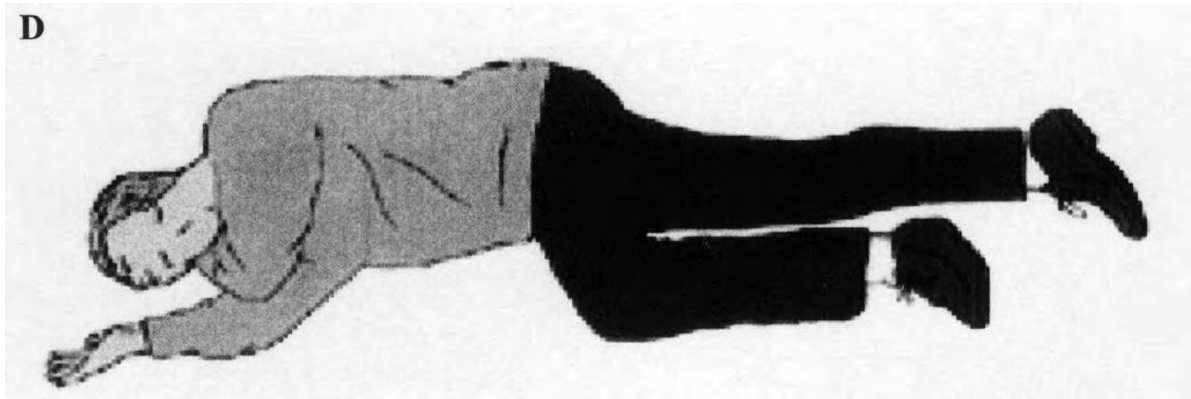


1. Opening the airway.



2. External cardiac massage.





3. Recovery position. a/ b/ c/ d/

AUTOMATIC EXTERNAL DEFIBRILATION – AED

In some circumstances rescuers may use AED if earlier trained. Electrical defibrillation is essential therapy when CA is due to ventricular fibrillation (VF) or pulse less ventricular tachycardia (PVT) and the outcome depends on time between CA and defibrillation. That is why popularity of Public Access Defibrillation (PAD) becomes wider; one may observe better results of CPR when AED is used during BLS, still before qualified services arrival. Using AED is just attaching electrodes as quickly as possible during BLS procedure and respecting audio-visual guidelines. These guidelines are: single defibrillations when mechanism of CA is VF or PVT; immediate CPR after defibrillation without pulse and breath assessment; 2 minutes of continuous CPR before another assessment of rhythm, breath or pulse.

APPLICATION OF UNI-, BI- AND TRIAXIAL SWATHES

GENERAL AIMS: training the ability of bandaging different parts of the body

The purpose of this procedure is skilful application of swathes, proper selection of a bandage and the type of swathe.

Detailed purposes of bandaging:

- fixing a dressing
- sealing, warming up and fixing a compress
- immobilizing joints or limbs
- strengthening and immobilizing integuments e.g. after surgery
- compression of blood vessels, preventing venostasis /management of venous leg ulceration/

PRINCIPLES:

- the bandage should be rolled tightly and regularly, with its “head” up
- the beginning of the bandage should be left in the fingers of the left hand and “the head” of the bandage - in the right hand
- bandage from left to right
- unwind the bandage gradually while putting it on
- prevent it from dropping
- begin with putting a circular swathe above or under the place of bandaging
- avoid shifting the dressing
- put the bandage on carefully so that it adhered precisely to the surface of the skin
- it should not be put too tightly
- swathes should be regular, aesthetic and stable

- proper choice of a bandage should be made – the type and appropriate width – depending on the part of the body and a sort of dressing
- while performing the procedure observe a patient, communicate, stand or sit opposite the bandaged part
- be concerned about patient's comfort and safety
- while taking off the bandage put it from one hand to the other, the patient remains still
- protect the parts that are exposed to compression with a liner
- a piece of cotton wool should isolate two contacting skin surfaces
- provided parts should be controlled for secondary injuries /edema, pain, dysesthesia/
- make an assessment of the need and efficacy of the dressing
- regularly perform motor exercises of both the healthy and dressed limb - contracture prevention

FUNCTIONS OF BANDAGES:

- protection from microbial infections
- protection of the surrounding from germs /infected wounds/
- immobilization of particular parts of the body
- arresting bleeding and relieving pain
- compression /e.g. in intra-articular effusion/
- supporting /e.g. in dislocations/

Dressing materials:

- adhesive tapes
- belt bandages
- bandages for many sorts of dressings
- gauze bandages
- elastic bandages

- collodion bandages
- plaster bandages
- cellulose bandages
- spray bandages
- dressing knitwears
- knitted dressings with or without an applicator
- liner materials

TYPES OF BANDAGES:

- knitted – gauze – mostly used to hold a dressing on body regions that are easily accessible
- knitted – rough viscose knitwear – used to hold a dressing
- elastic – of warp strand, that is elastic and stretchy
- cohesive – supplemented with latex, with adhesive properties – used to hold a dressing

TYPES OF SWATHES:

1. CIRCULAR – every layer covers completely the previous one
2. HELICAL – following layer covers 2/3 of the previous one
3. SERPENTINE – oblique swathes, gaps between
4. REVERSE - resembles a serpentine but a bandage is turned ” head” down in the middle of a swathe
5. SPICA : figure-of-eight dressing around axis
 - ASCENDING SPICA- figure-of-eight dressing with crosses heading for the heart - upwards
 - DESCENDING SPICA - figure-of-eight dressing with crosses heading from the heart –downwards
6. OBLIQUE:
 - CONVERGENT – eight-shaped swathes, crossing in flexions of joints; start bandaging above or below a joint

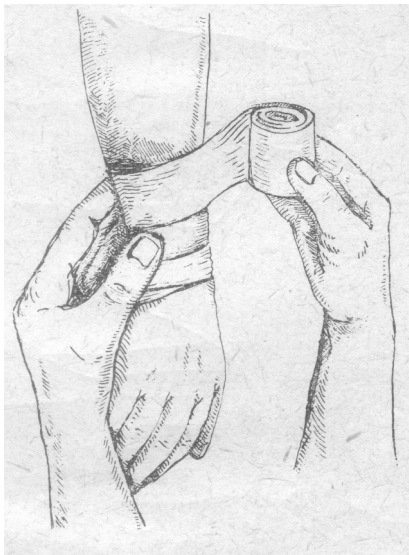- **DIVERGENT** – eight-shaped swathes; start bandaging in a flexion of a joint and end above or below

The following types of swathes are distinguished depending on the number of parts of the body that are covered:

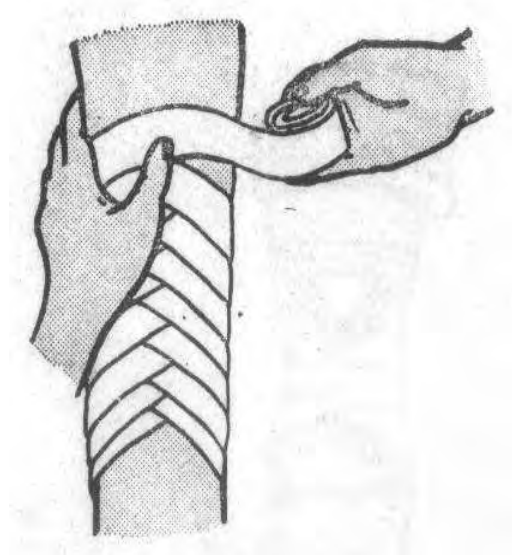
- **UNIAXIAL SWATHES**

Including:

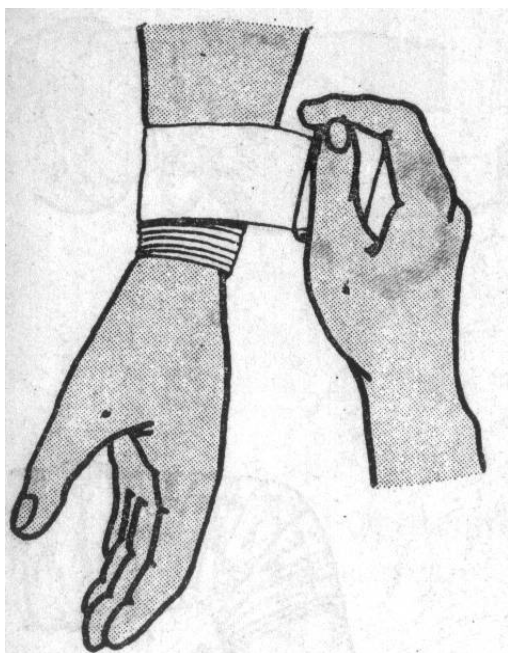
- circular swathe
- reverse swathe
- helical swathe
- serpentine swathe



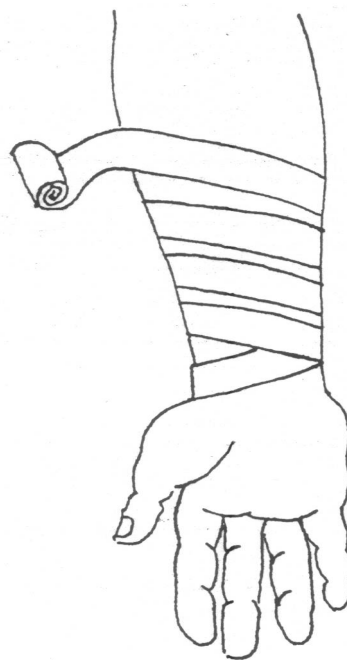
Helical swathe



Reverse swathe



Circular swathe

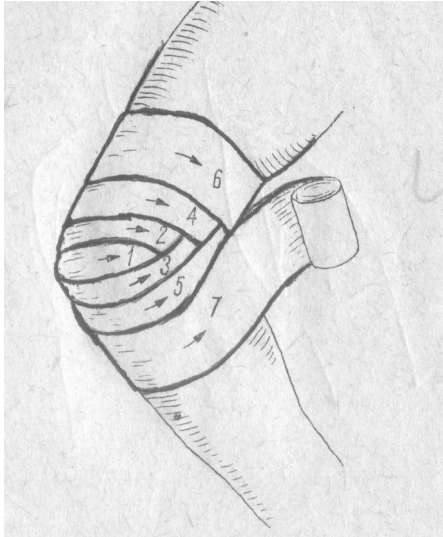


Serpentine swathe

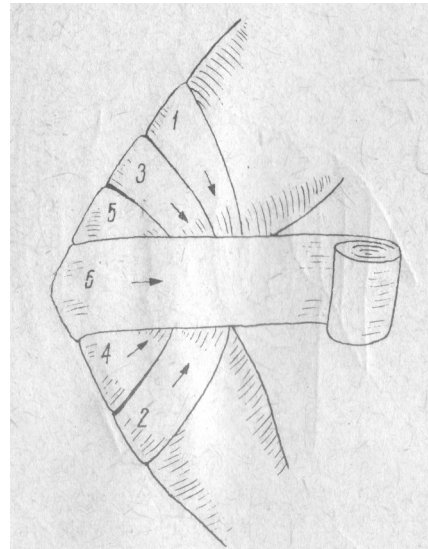
- **BIAXIAL SWATHES**

Including:

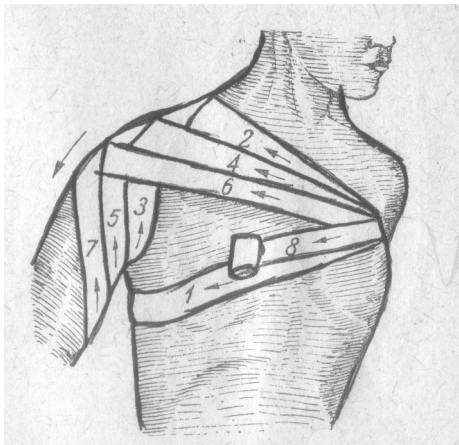
- oblique convergent and divergent swathes
- spica ascending and descending dressings



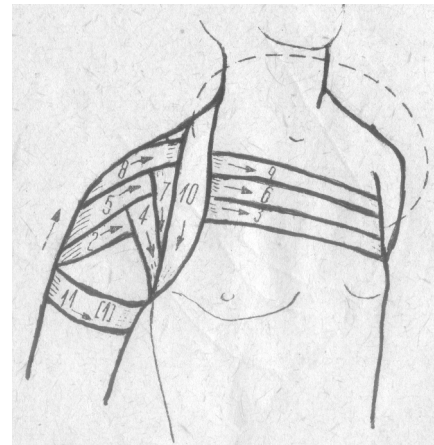
Oblique divergent swathe



Oblique convergent swathe

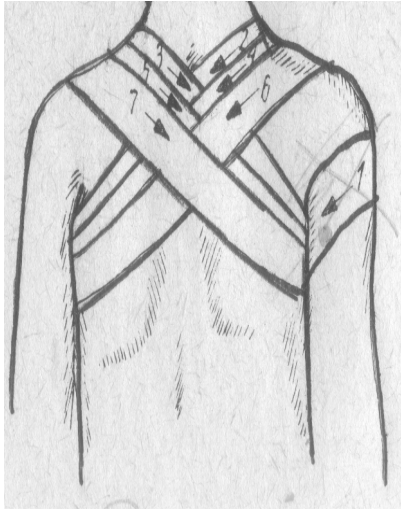


Spica descending dressing

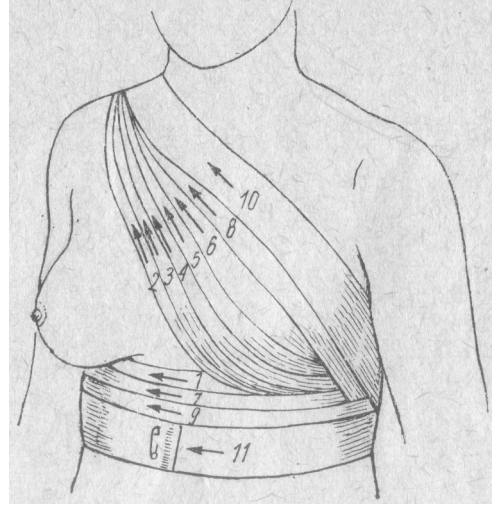


Spica ascending dressing

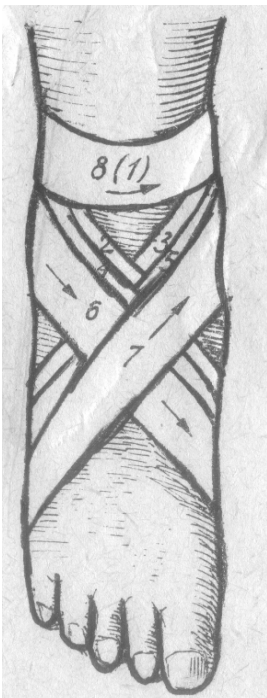
- **TRIAxIAL SWATHES**



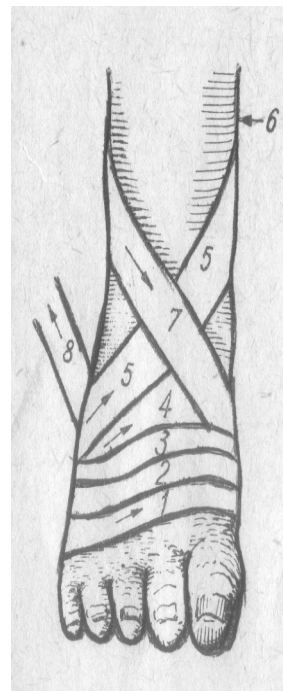
Spica dressing of a nape



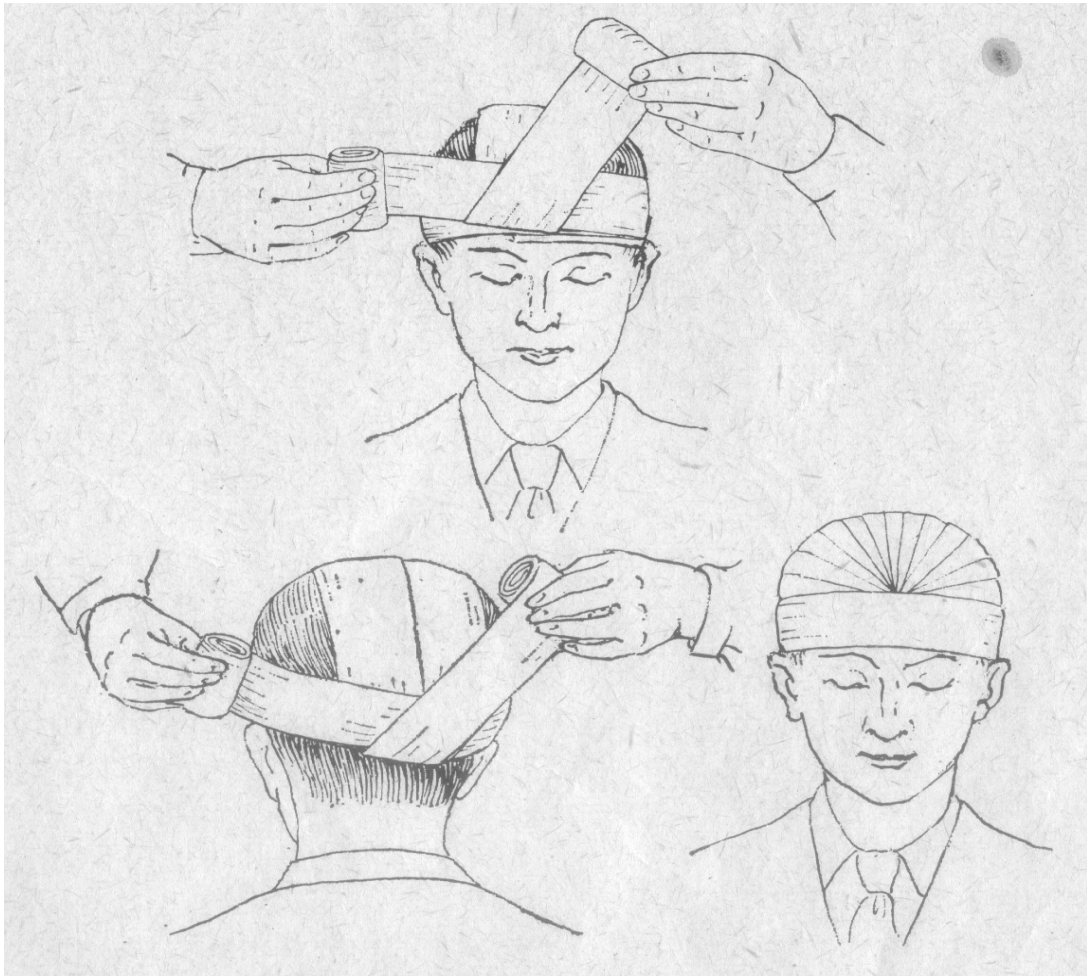
Dressing of a breast



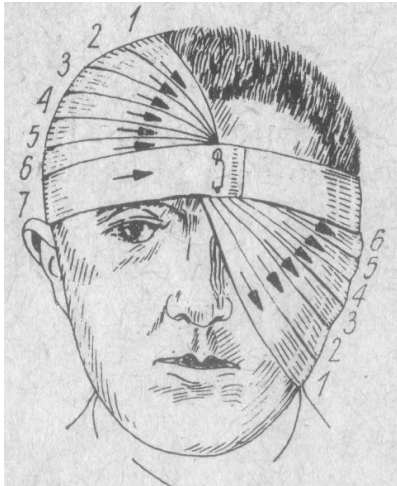
Spica descending dressing of a foot



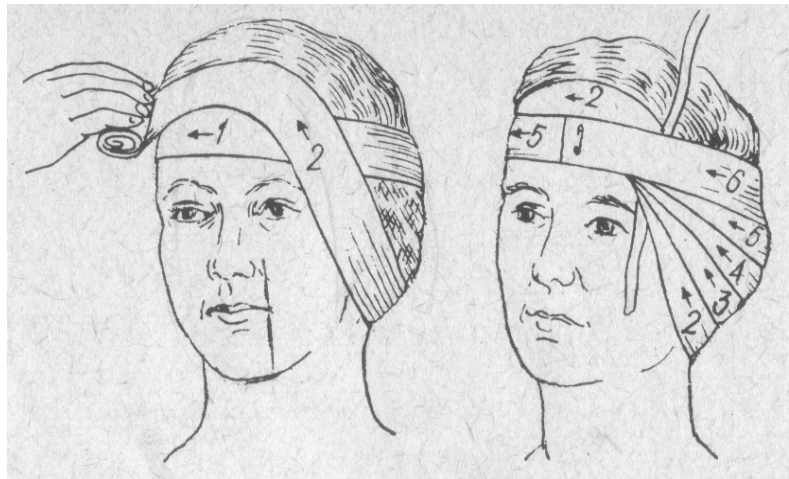
Spica ascending dressing of a foot



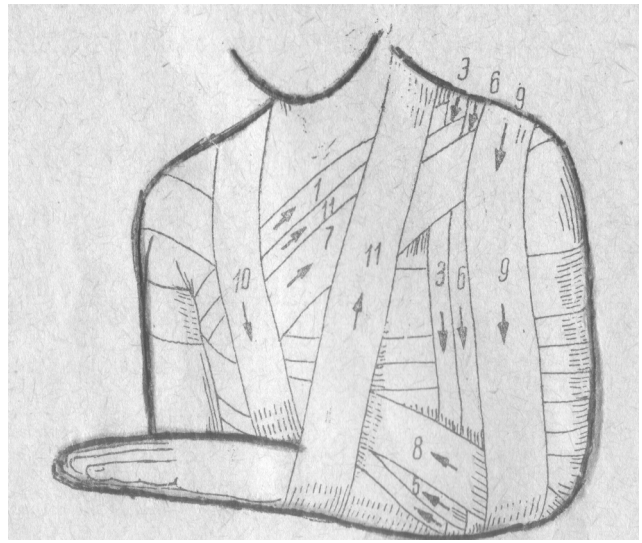
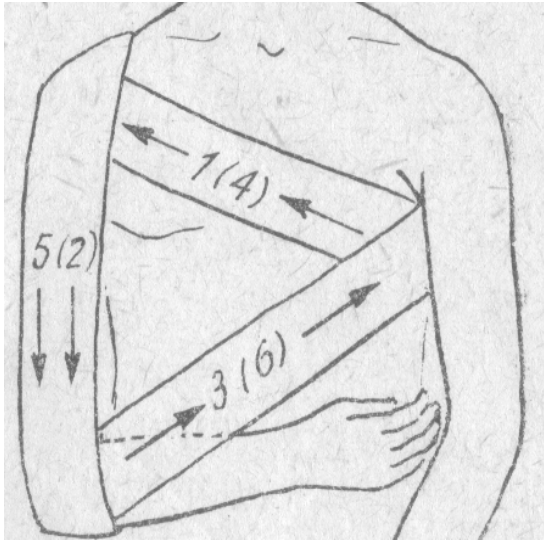
Hippocratic cap-shaped bandage



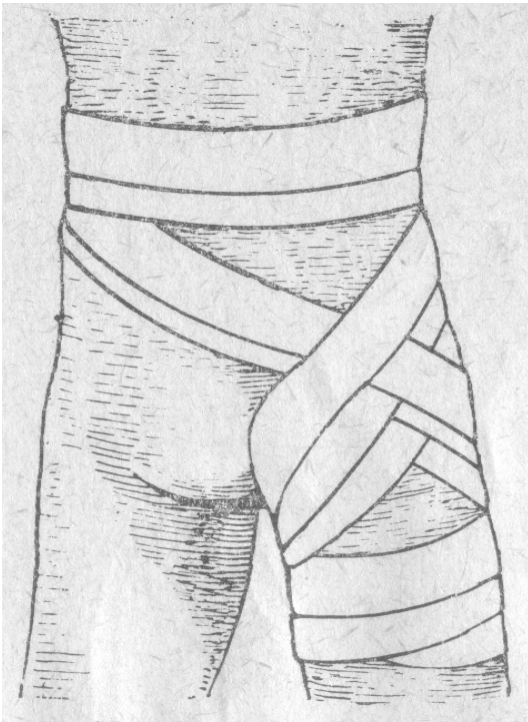
Eye dressing



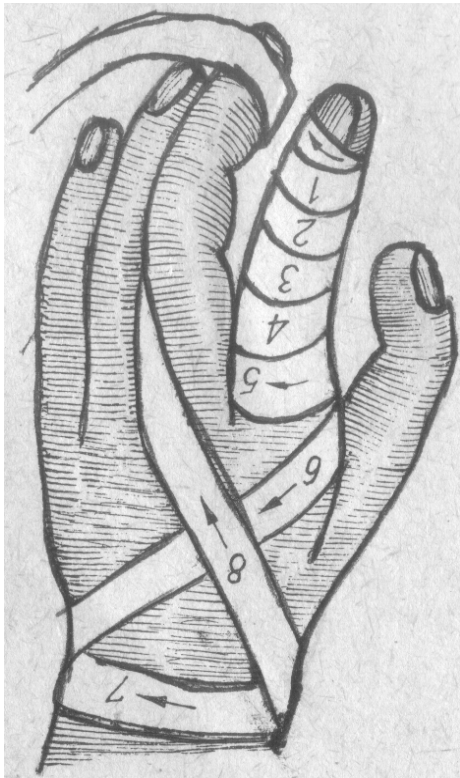
Ear dressing



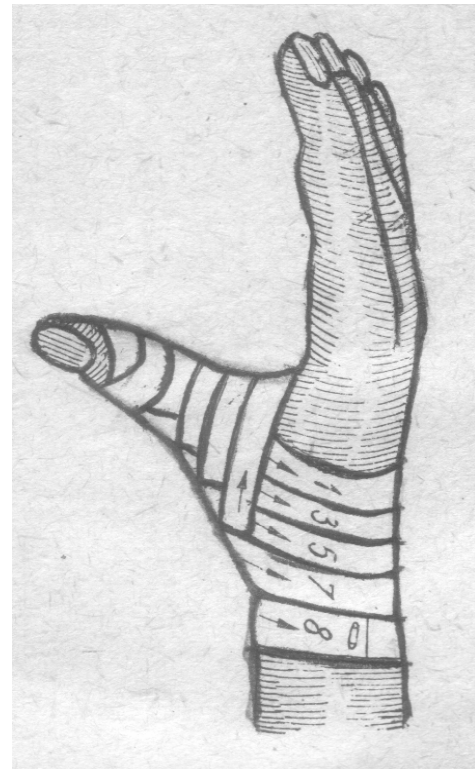
Desault's dressing



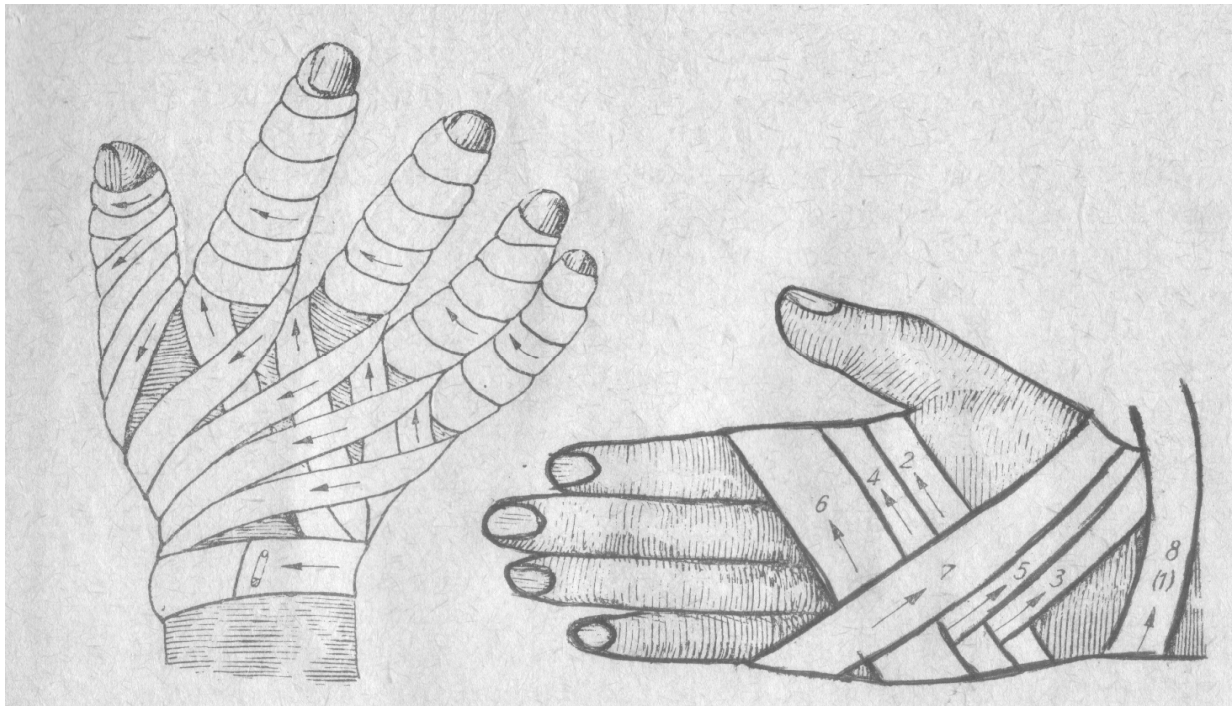
Buttock dressing



Helical finger dressing



Spica ascending thumb dressing



Gauntlet bandage

Spica ascending dressing of a hand dorsum

DRESSING SLEEVES

Types:

- knitted
- transparent knitted

Description of dressing sleeves

Characteristics	Knitted sleeves	Transparent knitted sleeves
Composition	cotton or cellulose yarn, bleached or semi-bleached, small meshes, chain woven, do not tear	cotton wrapped with lycra or polyamid, polyurethan and polyamid or rubber strand, larger meshes, chain woven, do not tear
Function	- bandage fixing - wound protection - skin protection under plaster dressing, sling, splint	- bandage fixing
Elasticity	medium	high
Extensibility	medium longitudinal and transverse extensibility	high transverse extensibility, higher than longitudinal

Advantages:

- practical, easy, fast to pull over or change
- aesthetic
- comfortable, adapting to natural body curvatures, do not strain, do not roll up, elastic on articular surfaces
- economical
- well tolerated by skin

Method of application:

- wash hands
- put a patient in a convenient position
- stand or sit opposite the place, where a sleeve will be placed
- choose an appropriate size of the sleeve
- pull the sleeve over the bandage
- assess and cut off the length of the sleeve that is needed
- cut the edge of the sleeve, pull and bind tips to fix the sleeve
- cut out an opening to uncover ears, eyes or other parts of a body

References:

1. Rutkowski J.: Nauka o opatrunkach (Desmurgia). PZWL Warszawa 1966r.
2. Ślusarska B., Zarzycka D., Zahradniczek K.: Podstawy pielęgniarstwa. Podręcznik dla studentów i absolwentów kierunków pielęgniarstwo i położnictwo. Lublin 2004, Tom II, 785-819.
3. Chrzęszczewska A.: Bandażowanie. PZWL Warszawa 1987
4. Słoma J. Przystosowanie obronne. PZWL Warszawa 2004,141-145.

THE TECHNIQUE OF THE INTRAVENOUS CANNULE INSERTION

Venous cannulation is a procedure that is most frequently performed in patients.

It is indicated in order to:

- Take blood specimens for laboratory tests.
- Administer a single dose of an intravenous drug.
- Administer prolonged intravenous therapy or to infuse a large amount of fluids.

In the first two cases, a single puncture with a disposable metal needle is required, in the last one - soft, plastic cannules that are fixed on needles should be used. Cannulation is indeed a very unpleasant experience for patients, and particularly for children. A brief explanation of the procedure should be made before you start performing it. Try to come into contact with older children, inform about unpleasant moments during the procedure. EMLA cream may be applied in children about an hour before to anesthetize the area of puncture. It is also possible to inject the area of the cannulated vein using 1% lignocaine and a very fine needle.

Selecting veins

A general rule is to puncture peripheral veins (hand, foot), picking the areas of possibly low range of skin mobility (avoid joint area), sparing veins of the cubital fossa (sometimes, access to central veins can be obtained through the ulnar vein or endocavitational electrodes may be introduced this way; besides, the risk of an incidental puncture of the adjacent artery should not be ignored). Technical difficulties and the severe condition of the patient may be the exceptions. Pick a vein that is well visible and whose diameter enables applying an appropriate cannule. Start puncturing from the distal part of the picked vessel. If veins are not visible try to localize them on palpation. Try to apply thick cannules, particularly in patients in the severe condition, in whom massive fluid or blood substitute infusions are planned. In right-handed patients - try their left hand first.

- Prepare the necessary equipment:

metal needles - 1,1 mm to take blood specimens

0.7- 0.8 mm to administer drugs

plastic cannules

gauze swabs soaked with alcohol based solution or other antiseptics

tourniquet or sphygmomanometer

syringe, latex gloves, dressing, tape, dry gauzes

- Patient should sit or stay in the supine position. An extremity with the selected vein should be stabilized. Position should be convenient for the patient, as well as for the performer.
- Put on the tourniquet or sphygmomanometer pumped to about 50 mm Hg on the extremity, above the point of puncture to shut off the venous blood flow.

If the vessels are poorly visible we can

- ask the patient to bend and strengthen fingers "work the hand"

- put the extremity down

- clap the place of cannulation

- after relieving the tourniquet put on a warm compress, e.g. on the hand and forearm for 20 minutes to let the superficial veins dilate

- Put on the gloves.
- Hold patient's limb with your left hand so that the thumb could rest on the skin about 5 cm below the point of puncture, stretch the skin in the distal direction (not too tight in order to avoid flattening the vessel)- it stabilizes the vein which, especially in the older and emaciated, tends to draw aside from the needle's end.
- Clean the place of needle insertion with a swab soaked with alcohol (change swabs 3 times).
- Puncture with the metal needle attached to a syringe while leading the needle on the skin in an upward direction at an angle of 30°, with beveled surface up; after puncturing the skin and the vessel's wall (perceptible loss of resistance) put the needle right by the skin, move it gently forward and aspirate to the syringe.

If you want to administer drugs this way, relieve the tourniquet and dose the drug from the syringe only after assuring that the needle is in the lumen of the vein.

Then draw the needle back, cover the point of puncture with an aseptic swab and press it for 2-3 minutes.

- While inserting a plastic cannule, the position of the needle is identical; blood should appear at the end of the cannule after puncturing the vessel.

There are two methods of inserting the plastic part to the vessel. The first one involves pulling back a metal mandrel and inserting the plastic part into the vessel at the same time. The second one consists of pulling back the mandrel while the blood flow is still present, connecting the syringe and dosing the fluid while putting the plastic part into the vessel.

If there are any difficulties with puncturing the vessel, never insert the mandrel into the cannule again if it is still in the vessel. It may cause its damaging and embolic complications. Reapplication is performed after pulling back the cannule under the sight control.

Having put the cannule, flush its lumen with a couple of milliliters of liquid that is administered through the syringe. If you find no resistance while flushing the cannula, no outflow of blood after disconnecting the syringe, no skin bulging at the end of the cannula and no pain claimed on injecting the liquid then, the you can consider the location of the cannula appropriate. Sometimes, the end of the plastic cannul may be lodged in a valve, which blocks the cannule and limits its flow. To avoid such a situation, try to pull the cannula about 0,5 cm back and fix it again.

- At the end of the procedure clean and dry the skin around the insertion and fix the cannula to the skin. Adhesive foils are the best solution but if these are not available you can use tapes.
- The place of cannulation should be checked every day for swelling, tenderness and reddening. If positive, such symptoms mean phlebitis and demand removing the cannule. Tenderness near the place of cannulation, enlarged limb's girth, slow drip flow or local drop in temperature and liquid leakage suggest vein damage and demand removing the cannule as well.

If leakage of tissue irritant fluid occurs, the area should be injected with 1% lignocaine and supplied with warm compress.

External jugular vein cannulation

The course of the external jugular vein needs precise examination. It runs obliquely on the surface of sternocleidomastoid muscle, sometimes as two parallel vessels. It is visible in 85% of patients. It is a vein with a relatively big diameter, which enables to insert a catheter to vena cava superior.

If it is impossible to cannulate peripheral vessels, the external jugular vein should be considered for cannulation.

Cannulation is performed in supine position, with a pillow under patient's shoulders. Lower the head by 20-30 degrees and turn patient's head slightly in the direction opposite to the cannulated side. For a better exposure of the vein, pull it just over the clavicle or ask the patient to perform Valsalva test. External jugular vein runs loosely in the surrounding tissues, which may cause troubles on puncturing. Cannulation technique follows the one that has been described above. Insert the needle at a smaller angle and mind the vein's superficial location.

Methods of wound suturing

Surgical suturing is a sequence of procedures aimed at constructing continuity of teguments and tissues or organs.

Wound suturing is preceded with disinfection and cleansing of all impurities, removal of foreign bodies and damaged tissues if needed.

The aim of suturing is to provide proper conditions for healing by “first intention” (*sanatio vulneris per primam intentionem*), which guarantees the best cosmetic and functional results.

Surgical instruments used for wound suturing

1. Instruments used for grasping and holding

Tweezers are basic surgical instruments, which are used for holding tissues and controlling a needle inserted with a holder.

There are two types of tweezers distinguished:

- *surgical tweezers (dissecting forceps)* with the ends serrated alternately on the edges /fig. 1/, used mainly for suturing skin or more dense tissues

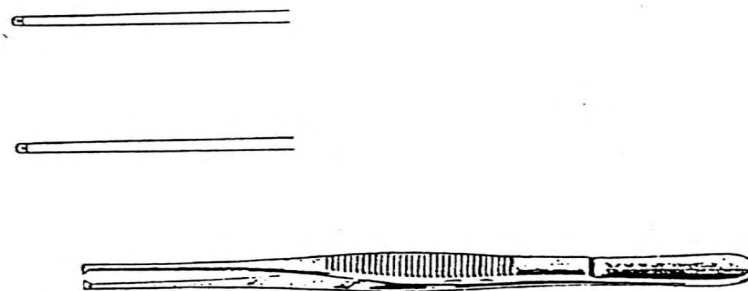


Fig. 1

- *anatomic tweezers (dissecting forceps)* with oval or right ends and slight transverse grooves on the surface /fig. 2/ used for holding fragile and tender tissues and for their preparation

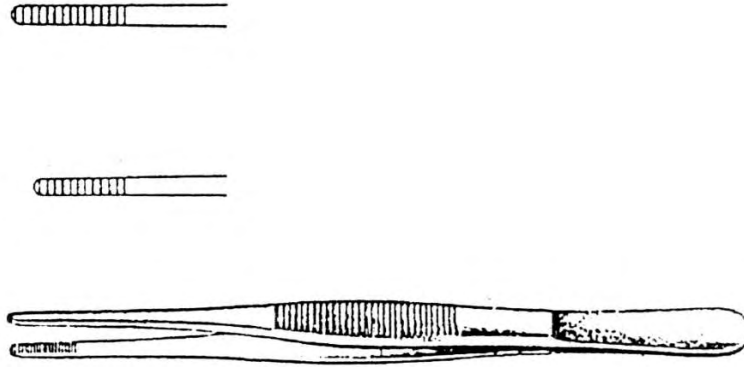


Fig. 2

A pair of tweezers is held like a pen and stabilized between the thumb, the forefinger and the middle finger /fig. 3/. While suturing the wound, it is usually kept in the left hand.

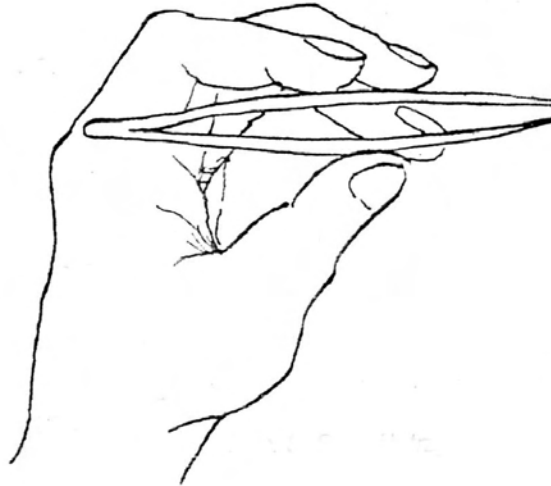


Fig. 3

Another type of instruments used to catch and hold tissues are *forceps*.

Most common forceps include:

- *Pean forceps* with straight or slightly bent ends; serve as a haemostatic instrument /fig. 4/

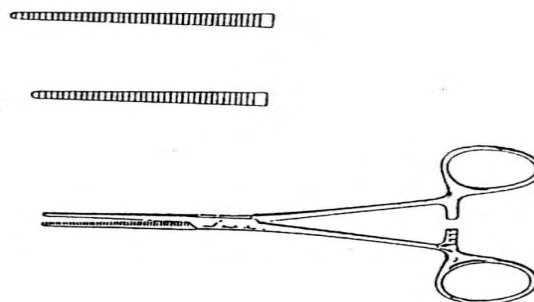


Fig. 4

- *Kocher forceps* with straight and sharply serrated ends; used to catch fasciae and muscles

/fig. 5/

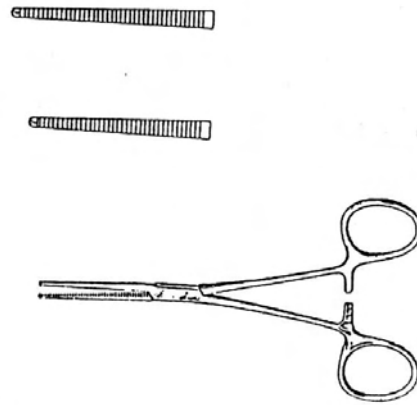


Fig. 5

- *Chaput forceps* with soft blades and slightly serrated ends; used to hold tender and fragile tissues as the intestine or cyst wall /fig. 6/

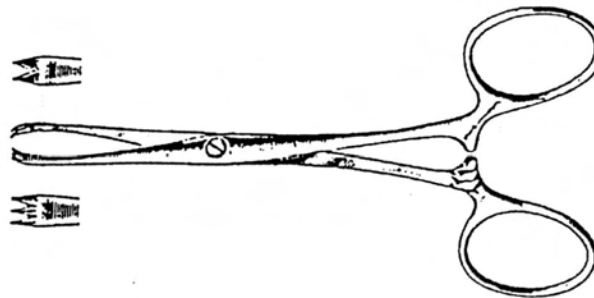


Fig. 6

2. Instruments useful for holding the surgical needle while suturing

To hold a suturing needle various types of needle-holders are used.

Hegar needle-holder is commonly used nowadays /fig. 7/. It is a needle-holder with two arms that are able to lock: short – designed for precise sutures, long - for deep surgical fields. It is held with the thumb and ring-finger placed in handles while the forefinger and the middle finger additionally stabilize the distal arm of the needle-holder /fig. 8/.

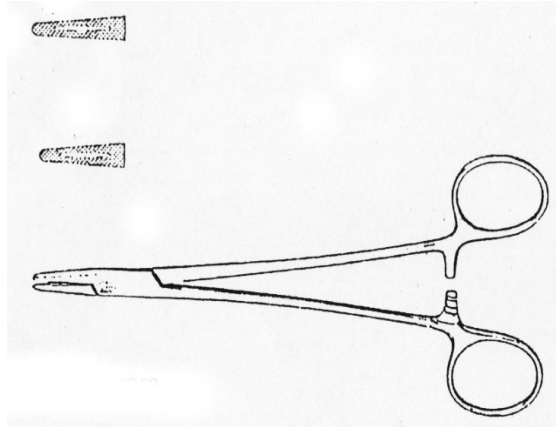


Fig. 7

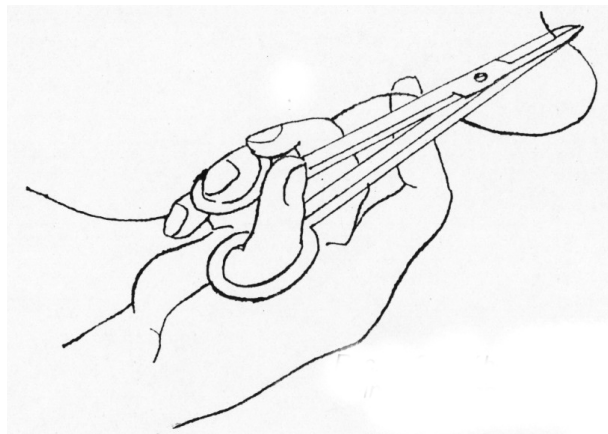


Fig. 8

3. Scissors

Surgical scissors are used for preparing, cutting tissues and cutting threads after suture binding. *Mayo-Harrington* or *Mayo* scissors are commonly used for tissue preparation. Its bent blades facilitate surgery.

Simple scissors specifically serve for cutting surgical threads and sutures.

Scissors are held with the thumb and the third finger aligned in handles; the middle finger is at the base of the handle; in addition, the forefinger, which stabilizes the instrument rests on its hinge.

Types of surgical needles

1. Curved needles

The sutures with curved needles require needle-holders. Properly, the needle should be shut in a needle-holder in $\frac{2}{3}$ of its length counting from the thread or the eye, in a way enabling ends of the needle-holder to protrude on the other side of the needle /fig. 9/.

Varying extent of needle curvatures, defined by circle fraction, enables the surgeon to choose the best profile in order to apply the suture precisely and gently, even in anatomically challenging circumstances /fig 10/. Needles with prominent curvature profiles should be used for sutures in depth of an operating field, where there is little space to move the needle round easily. It is recommended that the needle should be three times longer than the thickness of the connected tissues.

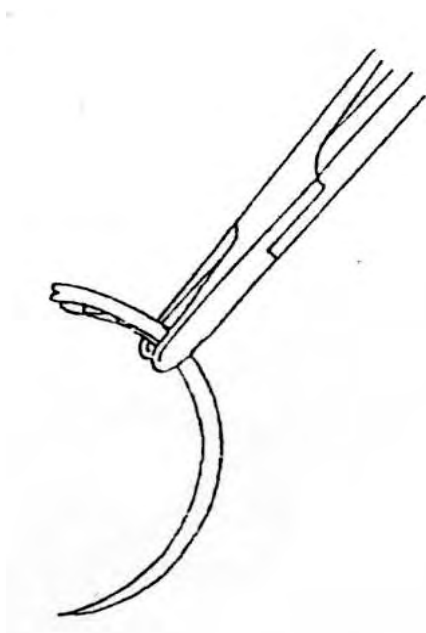


Fig. 9

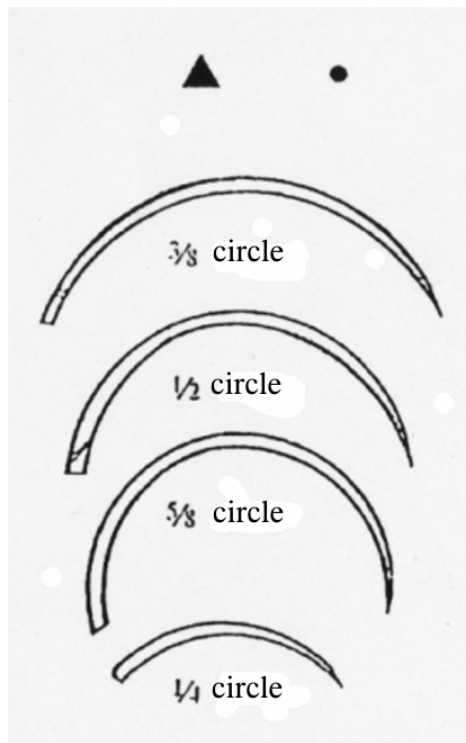


Fig. 10

2. Straight needles

Nowadays, this kind of needles is used rarely in clinical practice. While suturing, straight needle is grasped right with fingers /fig. 11/.

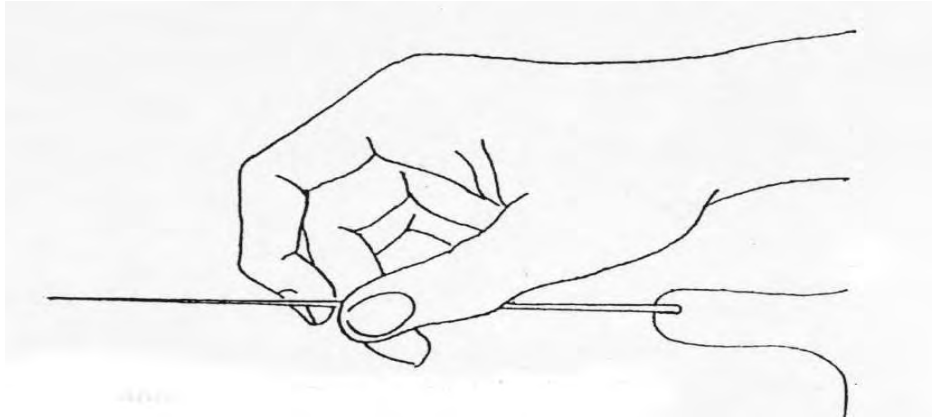


Fig. 11

All the types of needles regardless of their shape, can be divided into **cutting needles**, also called sharp (triangular cross-section) and **cylindrical needles** (round section) /fig. 10/.

Needles with eyes that need threading become less common.

Nowadays, we use the so-called atraumatic sutures with a thread fused with the needle. In this type of suture a tunnel that is not wider than the needle itself is formed in the tissues, which helps limit surgical trauma.

Types of surgical threads

Materials, which the threads are made of, are divided into absorbable and non-absorbable ones or natural and synthetic sutures. Non-absorbable sutures are applied on the skin and in septic wounds.

Absorbable threads, depending on their structure are divided into monofilament, polifilament, braided, plaits, coated and uncoated ones. Time of their absorbing is varied and depends on material properties; it can take from 14 days to 6 months. Absorbing progresses due to enzymatic disintegration and hydrolysis.

Always keep in mind that suturing cannot worsen or aggravate tissue trauma. Wound edges should be kept with in a gentle manner. Pulling, translocations or putting tissues on a needle is regarded as misconduct. It should always be made most of the needle's profile; inserting and withdrawing the needle should be fluent and careful. The needle should be inserted into the sewed tissues at the right angle. The way of binding the sutures is crucial for normal wound healing. The first surgical knot is intended to bring closer and align the sewed edges. The second knot, which holds the first one, should be tighter. If the first knot is

pulled too tight, the loop is tight, which can cause tissue cutting, its compression and local ischemia. It results in weaker protection and worse healing.

The space between sutures depends on adaptation of the wound's edges and their tension. In case of a slight tension and easy adaptation, a distance between two stitches that is two times longer than the distance between the wound edge and the place of insertion is recommended.

Techniques of thread binding

There are two basic types of sutures:

- *interrupted suture*, (also called loop, knotted or noose suture)
- *continuous (chain) suture*
- Loop simple suture /fig. 12/

The figure shows the way of putting it. It is put in compact, tense tissues. Mostly used for skin suturing. Binding knots on one side of a wound is advised.

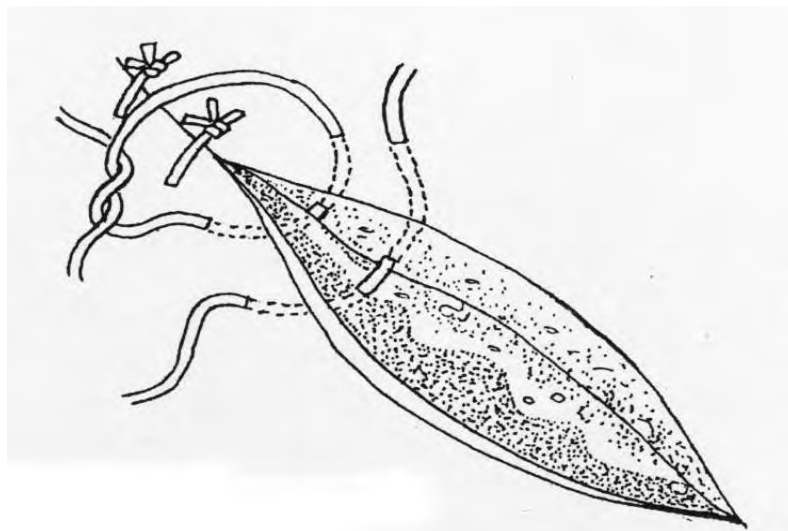


Fig. 12

- Loop buried suture (covered) /fig. 13/

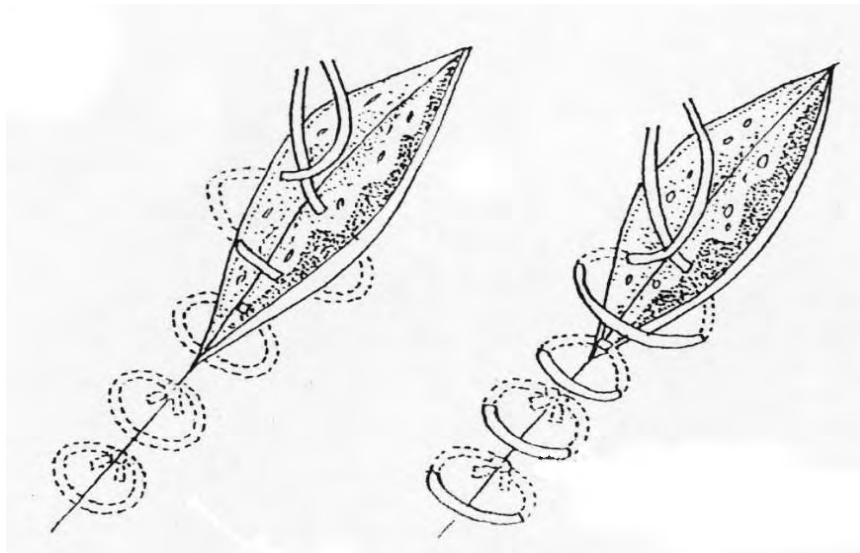


Fig. 13

The needle is inserted from an inside of the wound and emerges outside on the same side. Then it is inserted on the other edge from the outside to the inside of the wound. A knot is formed deep inside the wound. It is performed on a mucous membrane and subcutaneous adipose tissue.

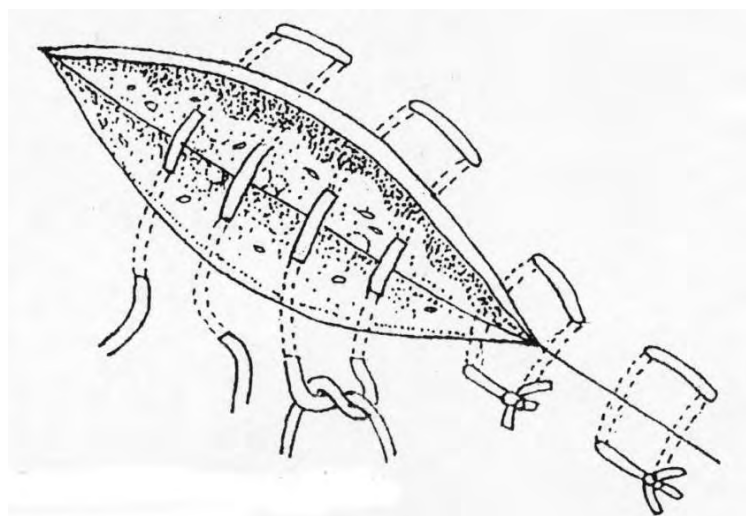


Fig. 14

- Mattress (blanket, quilted) transverse suture /fig. 14/

The needle is inserted from the outside of the proximal edge of the wound and led through the tissues to the other edge (like in the simple interrupted suture). Then, in the distance of 1 cm the same suture should be performed in the opposite direction. Thread's ends meet by the operator's side. Used for muscle and fascia suturing.

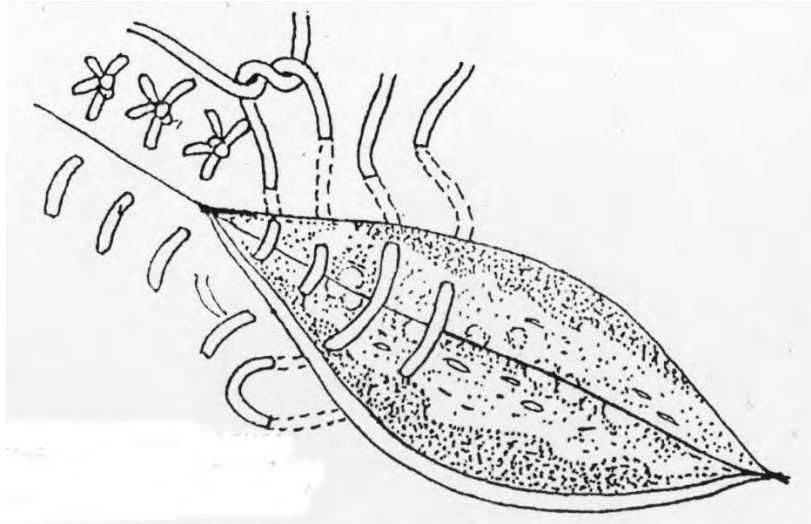


Fig. 15

- End-on mattress suture (cooptation) /fig. 15/

The needle is inserted from the outside, 1 cm from the proximal edge of the wound and withdrawn on the distal edge, symmetrically. Next, it is inserted superficially right by the distal edge and withdrawn on the proximal edge. This type of suture adapts the edges of a wound perfectly and is commonly used for skin suturing.

- Continuous over-and-over suture

Simple type: both edges of the wound are sutured with the needle directed slanted to its long axis; outside the thread appears crosswise to the long axis of the wound. /fig. 16/

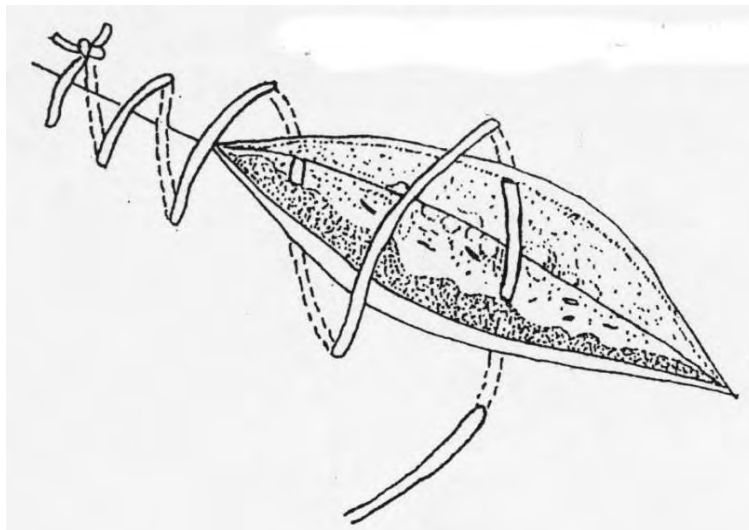


Fig. 16

Slanted type: both edges are sutured with the needle crossing the long axis of the

wound; finally the thread emerges slanted to the long axis of the wound /fig. 17/

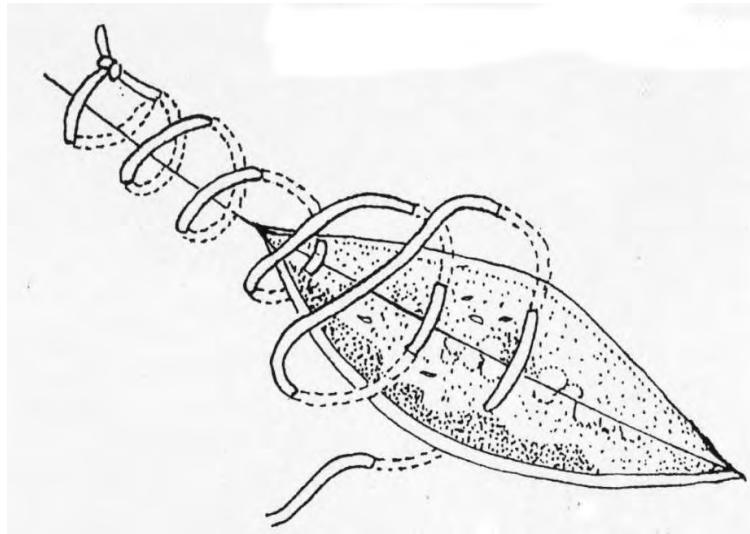


Fig. 17

- Continuous mattress suture /fig. 18/

After first insertion and thread binding, the needle is further inserted on the side of the previous withdrawing.

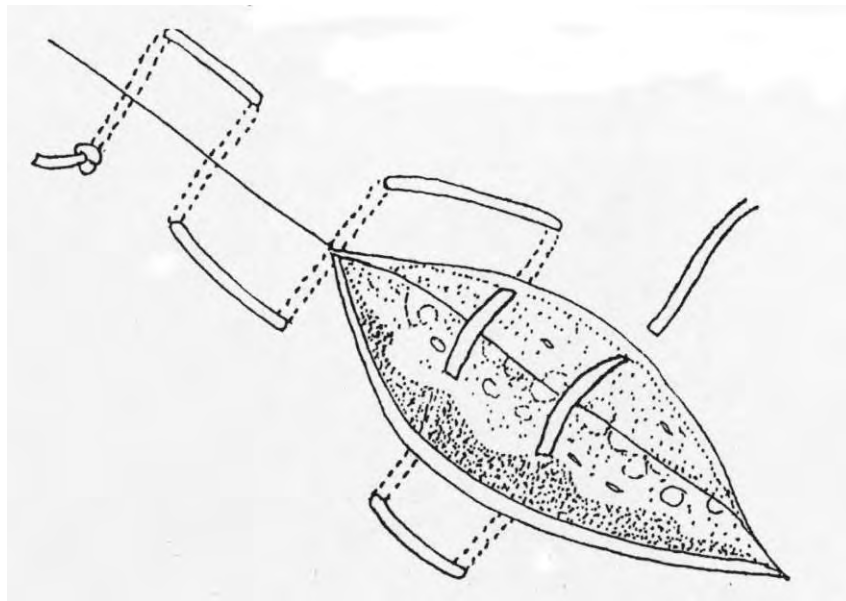


Fig. 18

- Continuous intracutaneous suture /fig. 19/

Continuous intracutaneous suture begins from the distal wound edge and from the left to right side. The needle is driven like in the mattress suture, but its insertion and withdrawing are performed on both sides in intracutaneous layer.

A perfect adaptation of wound edges, which results in satisfying cosmetic effect, is a

crucial advantage. By using absorbable materials one can avoid taking the stitches out.

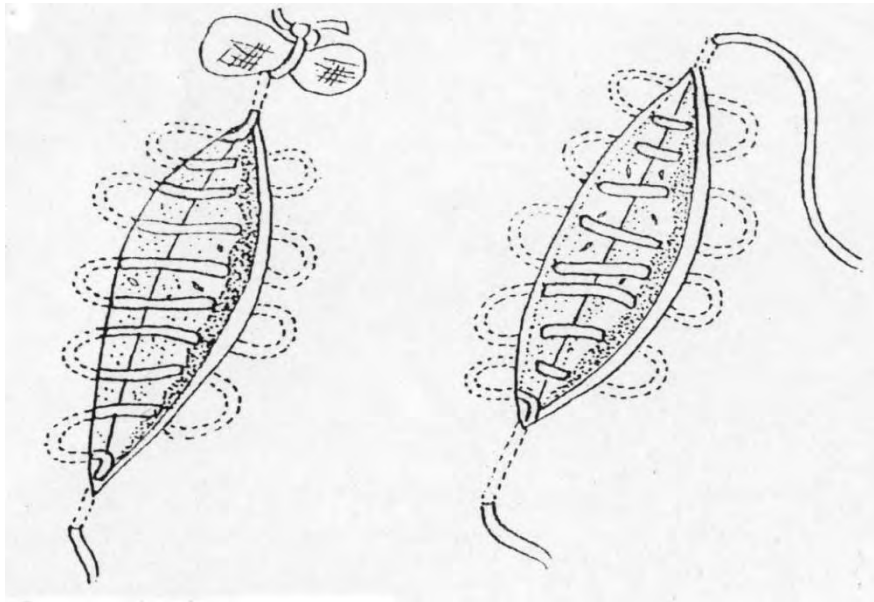


Fig. 19

Knotting

Two types of knots are often performed in surgery:

- Single knot
- Double knot, which is also referred to as surgical knot /fig.20/

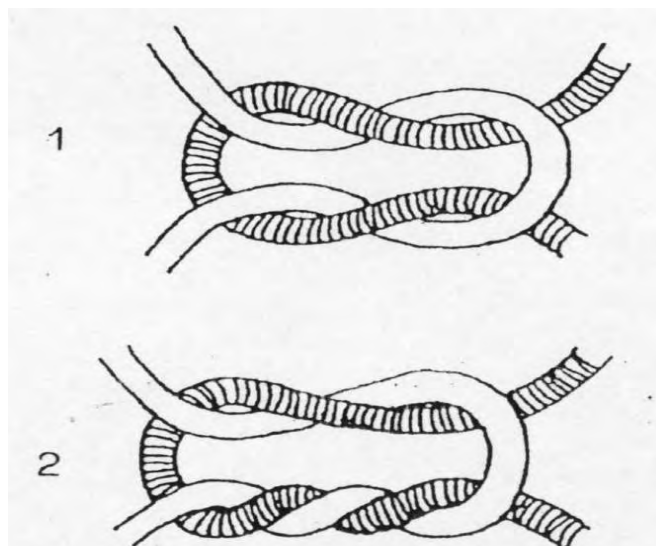


Fig. 20

The sutures are knotted manually (with one or both hands), or using instruments.

Mixed way of knotting seems to be the most useful method, considering the widespread use of atraumatic stitches /fig.21/.

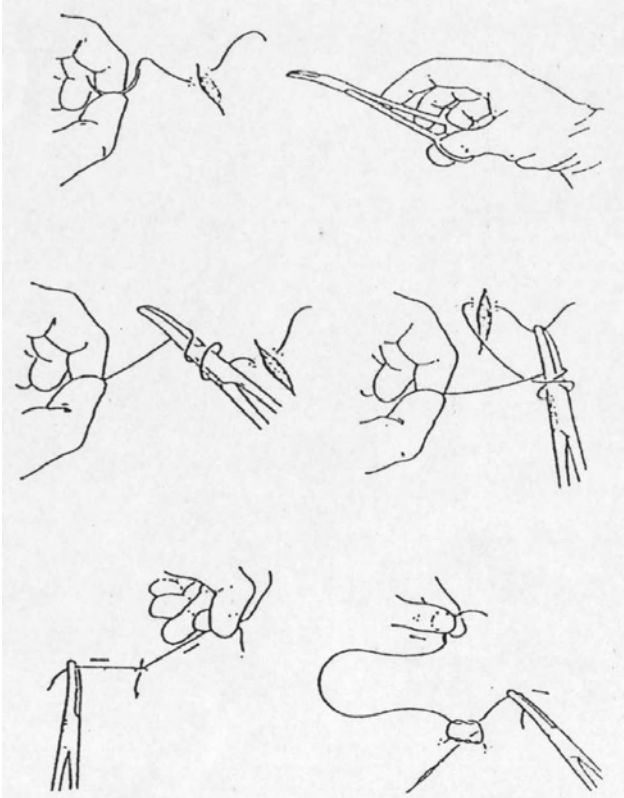


Fig. 21

Removing stitches

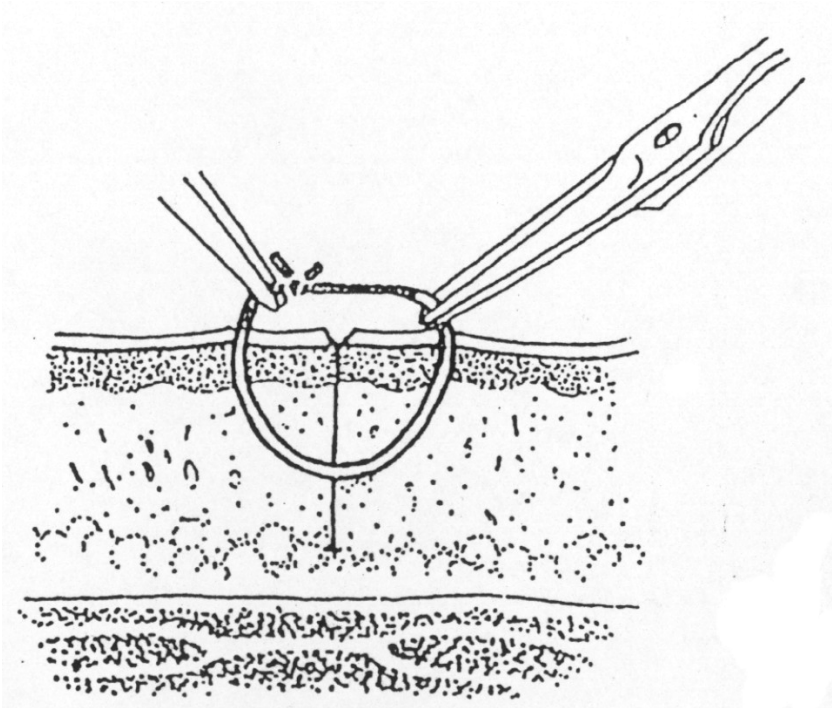


Fig. 22

On the average, time of keeping skin sutures takes from 5 to 7 days. After that period sutures should be removed. The suture should be pulled up from skin by tweezers or forceps to expose the part of the thread that is fixed in the skin. Cut the thread in that place and remove the suture by pulling it. This way dislocating the septic part of the suture (which remains there for the whole time of healing) through the suture channel can be avoided /fig. 22/.

Breast examination

Breast cancer is the most common neoplasm in women in developed countries. In Poland it accounts for 20% of malignant tumors in women, becoming the primary cause of death in women at the age 40-55. In recent years, the morbidity rate for breast cancer in Polish women has been 12,000 annually, of which almost 5,000 resulted in death. In about 5-10% of breast neoplasms, genetic predisposition is the primary cause. In the mid '90s, a strong relation between mutations in BRCA1 and BRCA2 genes (term derived from BReast CAncer) and familial history of breast cancer was established. With mutations as the underlying cause, neoplasm can be multifocal in one or both breasts, it grows and gives metastases more rapidly, and mutations carriers develop it earlier, even at the age of 30. Breast cancer risk increases with age, especially after menopause. The exact causes of breast cancer are not fully known yet, but hormonal disturbances and deficiencies seem to be the most probable culprit. In case a long-term activity of estrogens (early first menstruation, frequent anovulatory cycles, late menopause) or continuous estrogen activity (no births, no breast feeding), the risk of breast cancer increases. It markedly decreases in women who have had first three pregnancies; however further pregnancies and births do not seem to contribute to any deeper decrease in breast cancer rate. Other risk factors include previous excision of a non-malignant tumor, and environmental circumstances such as exposure to ionizing radiation at the early age, smoking, obesity, (particularly after menopause), fat-rich diet and alcohol abuse.

Detection of changes in the breast depends on routine medical check-ups, especially by an oncologist, regular breast scanning and mammography, and women's self-examination. If early detected, a tumor is usually small, and the smaller it is, the less probability of metastases. Early detection considerably improves prognosis in women with breast cancer. Mammography enables detection of breast cancer at least one year ahead of its manifestations. The smallest clinically palpable tumor is about 1 cm in size. Although mammography is the most effective screening test, in about 10-15% cases the tumor can remain undetected by this test, whereas it can be palpable in a clinical examination including self-examination.

The mean tumor size values in relation to various techniques applied:

- 40 mm in women who never perform self-examination
- 21 mm in women who perform self-examination sporadically

- 12 mm in women who regularly self-examine themselves
- 6 mm at first mammography
- 3 mm when mammography is performed regularly.

A helpful examination that is supplementary to mammography is ultrasonography, the so-called sonomammography. USG is a first-line examination if a woman below 30 years of age is found to have a nodule. It also helps determine if the mass palpated on the physical or visible in a mammography film is cystic or solid in nature. With the aid of USG, a fine-needle aspiration biopsy can be performed; however it is not as effective in detection of early stages of cancer, especially in screening tests. Another method is a biopsy-cut, which is the method of choice used mainly to diagnose small impalpable solid masses or microcalcification areas, which are visible only in a mammography film.

Clinical examination of the breasts

Physical examination of the breasts is an element of a routine clinical examination. In most women there are periodic thickenings or benign nodules in the breast and repeated clinical examination can focus on the sites that need more detailed diagnostic tests. Breast cancer is more common in the left rather than in the right breast; in half of the cases the primary focus occurs in the upper external quadrant of the breast, and in one fifth of cases it is central or hypopapillar. Breast cancer tends to metastasize to the lungs, bones, liver, adrenal glands and brain.

History of symptoms and signs

- asymmetry of the breasts with a sudden enlargement of one of them
- thickenings, nodules, indurations in the breast itself and in the armpit
- expansion of lesions such as warts or moles on the breast skin
- retraction of or exudate from the nipple
- pain, particularly when felt at one site only or one breast

Physical examination

A complete and correctly performed physical examination consists of two parts, inspection and palpation.

On **inspection**, the patient should be in a sitting or standing position

- a) with her arms loose along the body
- b) with her hands on her hips and shoulders thrust forward
- c) with her hands crossed behind her neck and body bent forward.

Each of these positions helps the physician to find and evaluate:

- outline and symmetry of both breasts, presence of skin lesions (ulceration, reddening), if the skin has orange-peel appearance with visible pointed pits
- presence of evident thickenings, irregularities, lumps or masses
- skin retraction
- nipple contraction and retraction
- shift of the nipple in relation to the nipple straight axis
- presence of thickenings and outgrowths, and skin discoloration around the neck and axilla

During **palpation**, the patient should be sitting or lying on her back. The arm of the examined side should be placed under her head to facilitate examination and then examination should be repeated with the arm down. If the breasts are large, the patient should be lying on her side and the breast opposite to the one on which the patient is lying should be examined. Examination must be bimanual.

Fig. 1. Circular clock-wise strokes with fingertips in the concentric system, around the whole of the gland from its widest circumference to the nipple

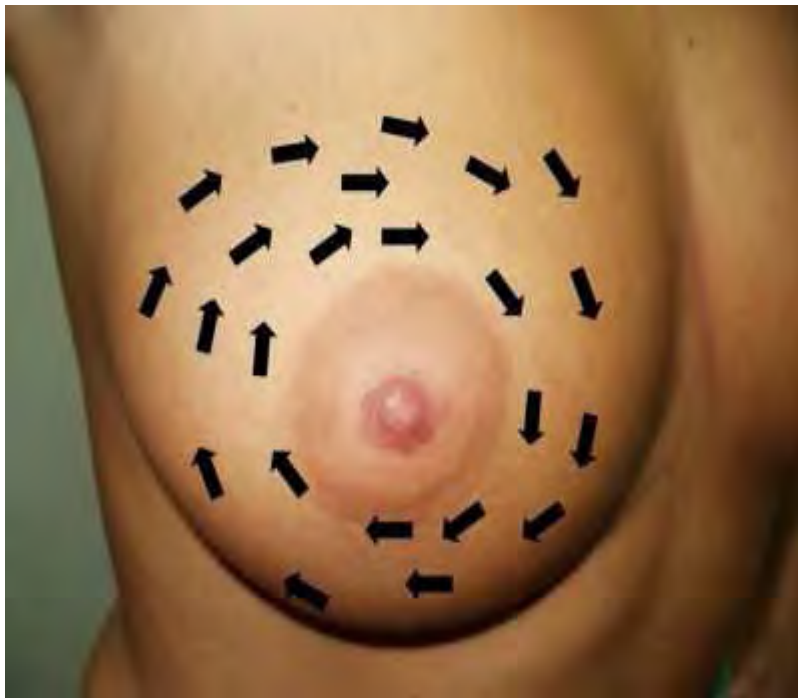
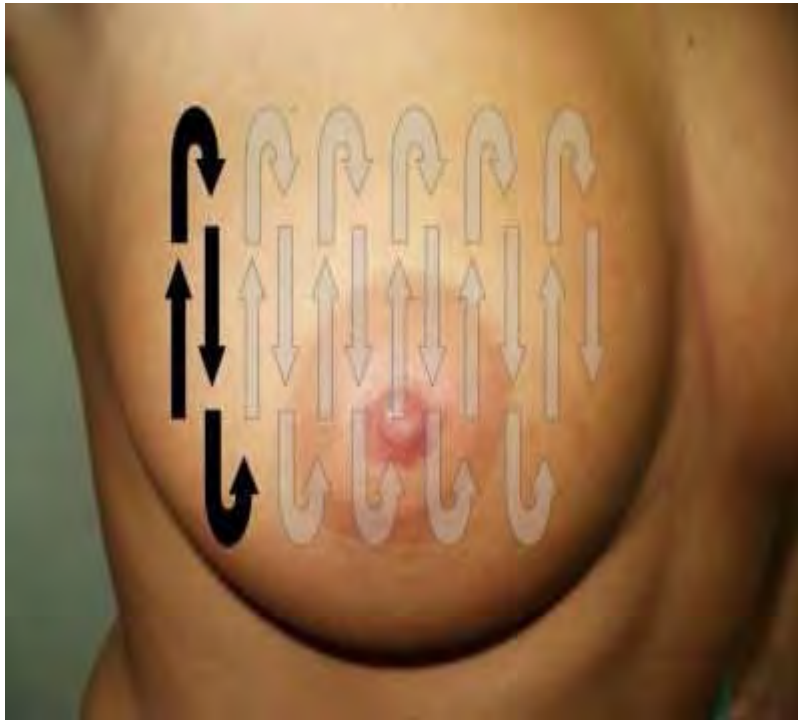


Fig.2. Circular strokes with fingertips in the radial system, i.e. from the nipple to the breast base
Examination should be started from the upper inner quadrant

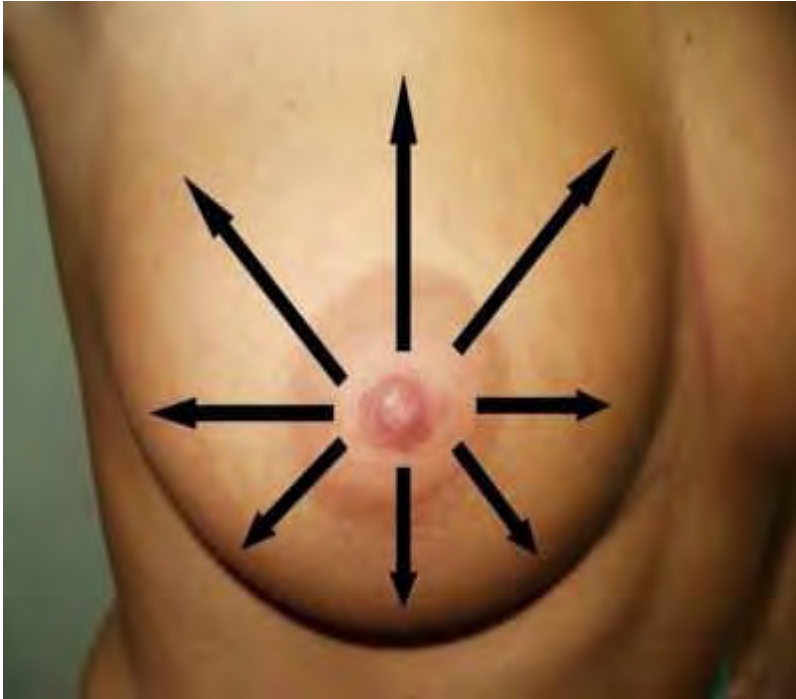

Fig. 3. Circular strokes with fingertips, in the 'up-down and down-up' system



(* photo: Przemysław Binkiewicz, <http://www.forumginekologiczne.pl>

By palpation the doctor assesses:

- Consistency (compactness, pliability) of both whole glands by examining their parenchyma on horizontal and vertical planes as well as along circular and diagonal lines (see Fig. 1, 2, and 3).
- Skin of the breasts, which should be felt with the whole palm surface, while the gland parenchyma and axilla - with the fingertips.
- Examination should be thorough and complete, including whole breasts and mammary papilla along with the areola and sub- and supra-clavicular region. When examining a supine patient, the doctor should lift and hold the patient's limb or slip a cushion under her shoulder, while inserting his other hand's fingers into the armpit as far as the thoracic wall.
- Gentle pressure in the subpapillar region will show if there is any exudate from the nipple.

To be certain that the entire breast tissue has been thoroughly investigated, such examination should last at least 5 minutes. In practice, however, the mean time for breast examination is about 2 minutes. It is therefore not surprising that detection of a primary breast tumor is often by a patient herself.

For diagnostic purposes, the breast is divided into four sections called quadrants: outer and inner, upper and lower, which facilitates description of localization of an investigated lesion. When describing a lesion, its size, shape, compactness, tenderness, depth in relation to the surface, change of position, and distance from the papilla should be noted. It is also necessary to examine the part of the breast called Spence's tail. If the examined axillary and supraclavicular glands are enlarged, in conglomerates, hard and not painful, they must always be suspected of metastases. The reports of the American Cancer Institute show that annual breast examination along with mammography decreases mortality due to breast cancer in women over 50 years of age by as much as 33%. Examination by palpation is of particular importance in 35-40 year old women in whom mammography is not performed regularly despite the fact that breast cancer is on the increase in this age group. In Poland over 50% of newly diagnosed breast cancers belong to advanced stages, and only 20-30% - to an early stage of the disease. In contrast, in the USA early, first-degree cancers account for 50-60%, and in Sweden – for 80%. Sadly, an increasing breast cancer morbidity and mortality reaching 50% as observed in Poland is a proof of ineffectiveness of early detection measures in our country.

Prophylactic measures:

- women over 30 years of age should perform self-examination every month for the rest of their lives. If they menstruate, they should carry out this examination after the menstruation, best after a bath. If they do not menstruate, they should fix the same day each month to do this.
- Women should undergo a control gynecologic examination at least once a year
- Over 50 years of age, a woman should have a mammography performed once a year, especially if she is at a high risk of developing breast cancer

Principles of catheterization – kinds of catheters

I. Catheterization

Regardless of the instrumental examination carried out in the urinary tract, it is obligatory to maintain perfectly sterile conditions, to apply analgesic and sedative drugs in order to alleviate patient's suffering, and to use gel substances that facilitate the introduction of the instrument into the urinary tract. While introducing instruments into the bladder, it is necessary to remember about overcoming the resistance of the urethral sphincter gently.

Full asepsis is guaranteed by the application of disposable instruments or repeated use of instruments, provided that they have been properly sterilized. The activities should be performed in an operating theatre, with the use of sterile disposable gloves.

Protection of the patient against suffering lies in administration of analgesic and sedative drugs 30 min before the operation.

Preparation of the operating zone includes rinsing the glans penis with aqueous solution of an antiseptic (0,5% hibitan solution). Administration of gel into the urethra facilitates the introduction of the instruments through an increase of slippage (lignocaine or xylocaine gel).

It is crucial to remember that catheterization can cause urethral damage and in extreme cases, it can result in forming a false tract due to introducing the catheter outside the light of the urinary tract.

II. Kinds of bladder catheters

Catheters have been popular and widely used in medicine since ancient times. Initially, the devices were made of metal: bronze or silver and later, of various kinds of metal alloys. These had an oval ending and a side aperture connected with the central canal, through which the urine was flowing out of the bladder. Metal catheters were of various curvatures and there were different ones for men and women. Nowadays, metal catheters are becoming obsolete and are substituted by catheters made of rubber, plastic, silicon or latex. It is now compulsory to use a catheter only once. Sterilization and repeated use of catheters is nowadays unacceptable. Sterilization of modern catheters changes the properties of the material that the catheters are made of, which may result in a prompt colonization of the catheter by microorganisms, and in extreme cases, it may lead to catheter damage and abandonment of its

fragments in the light of the urinary tract, which may expose patient to an increased risk of additional operations on the urinary tract.

The catheters most frequently used are those made of plastic, which very often is covered with substances that increase their resistance to colonization by microorganisms inhabiting the urinary tract and to the accumulation of crystals on their surface.

Catheters are divided into disposable and indwelling ones (left in the urinary tract for a long period of time). Among the catheters that are left in the urinary tract for a long period of time, there are catheters with the ability of self-retaining in the bladder and catheters that require additional attachment to the prostate to prevent them from slipping out of the bladder and the urethra. Catheter sizes are presented in the Charriere scale, which is an equivalent to the American French (Fr) scale and defines the caliber of each catheter as the diameter in millimeters times three. Thus a 1 mm diameter catheter is 3 Fr. One Charriere = 0.33mm. The diameter given in this scale corresponds to the external size of the device; its canal is adequately smaller. Many different varieties of catheters are utilized nowadays. They are most frequently named after their inventors. In my paper, I will present catheters that are applied in urological practice most frequently.

1. Single-use catheters

Nelaton catheter: it is ended with a semi-circular tip on the one end, with one side aperture connected to the catheter's central canal, which allows efficient and safe drainage of the urine (fig. 1). This type of catheter is eagerly used for single catheterization. It can be applied for calibration of the urethra to determine its diameter.



Fig. 1. Nelaton catheter.

Tiemann catheter: it has a conical curved ending and, similarly to Nelaton catheter, it has a side aperture that is connected with the central canal of the catheter (fig. 2). It is widely used in urethrostenosis and in men with enlarged prostate.



Fig. 2. Tiemann catheter.

Mercier catheter: it is designed similarly to Tiemann catheter and additionally, it has a crest on the side of the bending at the opposite end of the catheter, which enables to control the position of the rostrum while introducing the catheter into the bladder.

Couvelaire catheter: its intra-bladder ending is cut into the shape of a flute and it has two side apertures connected to the central canal. This type of catheter is widely used in patients with haematuria and to remove packing. It can be applied only when there is no urethrostenosis diagnosed.



Fig. 3. Couvelaire catheter

The above-mentioned catheters are used only once. Leaving them for a longer period of time requires attaching the catheter with an adhesive tape to prostate's skin, which is uncomfortable for the patient and does not guarantee its falling out of the bladder or the urethra.

2. Self-retaining catheters

This type of catheter is characterized by the presence of a balloon below the bladder ending. This balloon allows permanent maintenance of the catheter in the bladder without the need of sticking it by means of an adhesive tape to the skin of the prostate. The balloon is filled with sterile liquid by a special canal that runs in the catheter's wall. The canal and the balloon are connected with a valve in the peripheral part of the catheter. Through the catheter, sterile liquid is introduced by means of a syringe. The time of maintenance of such a catheter in the bladder cannot exceed 14 days.

A tendency that is visible is that all disposable catheters have their correspondents among the catheters that have an ability of self-retaining in the bladder.

Foley catheter: it is actually Nelaton catheter with a balloon that holds it in the bladder (fig. 4, 5). It is eagerly used in patients with urinary retention, who require long-term catheter maintenance in the bladder.

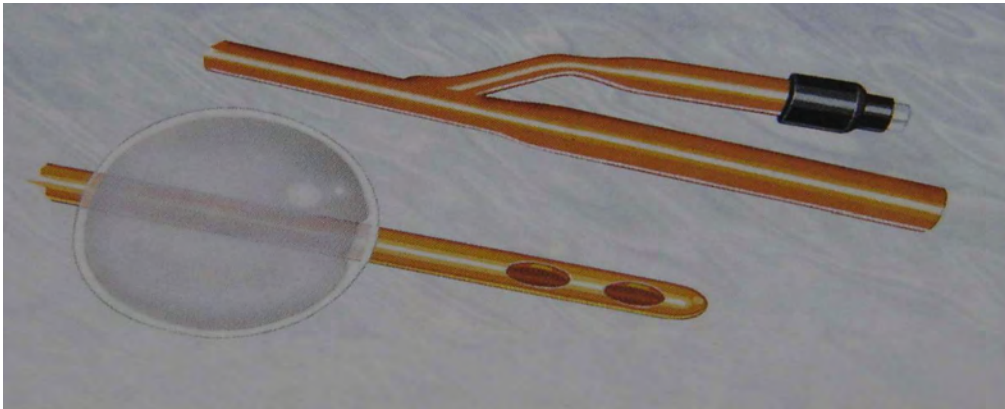


Fig. 4. Foley catheter with two apertures in the bladder part




Fig. 5. Foley catheter with one aperture in the bladder part

Dufour catheter: it is Tiemann catheter with a balloon and with an open-cut bladder ending and a side aperture connected to the central canal (fig. 6). This type of catheter is used after operations on the prostate gland, which require efficient drainage of the urine from the bladder very often with inclusion of blood and clots.

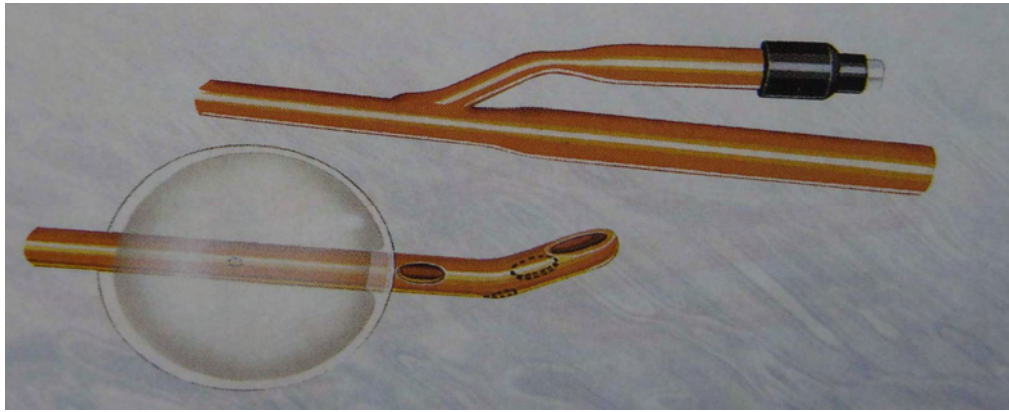


Fig. 6. Dufour catheter

The catheter after Couvelaire: the bladder ending of this catheter is cut in a slanting way. Two side apertures connected to the central canal ensure a very good drainage from the bladder. Fig. 7. The capacity of the balloon, 50 ml, allows applying this kind of catheter to stop bleeding from the cavum after operations on the prostate gland.

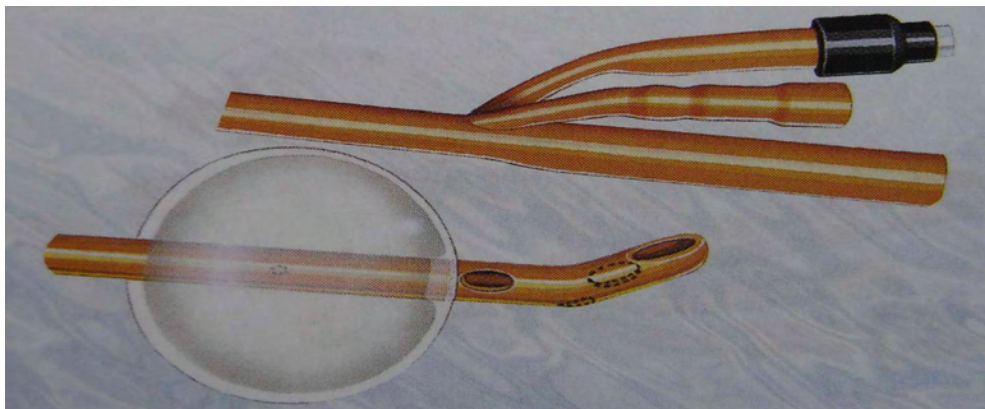


Fig. 7. Couvelaire's catheter with an additional canal ensuring constant rinsing of the bladder

Catheters that are able to self-maintain can have an additional canal for delivering rinsing liquid and are called double canals. These are used after operations on the prostate and the bladder, when there is danger of bleeding and formation of a tamponade.

3. Catheters with an ability to self-maintain in fistulas:

This is a group of catheters that secure efficient drainage of the urine from the bladder or kidney fistulas. These catheters are made of rubber and have a specially formed head that enables maintaining the catheter in the fistula. Catheters from this group that are most frequently used are as follows:

Pezzer's catheter: the head of this catheter is formed in the shape of a mushroom. There are apertures in the head that are connected with the central canal of the catheter (fig. 8). This kind of catheter is used in bladder fistulas. It is rarely used to drain urine through the urethra in women.




Fig. 8. Pezzer's catheter

Malecot's catheter: two arched rubber strips form the head directly over the central canal, in the shape of the letter "U". This catheter is used in bladder and kidney fistulas.

Cummings-Malecot's catheter: the basic part is Malecot's catheter but additionally, there is a thin catheter attached to the head and introduced into the light of the urinary tract, while the head of the catheter is placed in the light of the renal pelvis.



Fig. 9. Cummings-Malecot's catheter.

A catheter used in skin – kidney nephrostomy which necessitates draining the urine and splinting of the urinary tract. In order to introduce the catheter into the fistula or to exchange it, a metal conducting instrument is necessary. Nowadays, ready-made sets for the production and securing of vesical and kidney fistulas are widely used. In vesicle fistulas, we use the so-called “Cystofixy”, and in kidney fistulas – “Nefrofixy”.

IV. Catheters used for catheterization of the urinary tract

Among these catheters, there are diagnostic instruments, aiding tools to assist modern methods in the treatment of urolithiasis, as well as simple catheters for the drainage of the urine from kidneys or the urinary tract directly outside, and which are maintained in the urinary tracts, without any contact with the external environment.

Urethral catheters:

- with a semi-circular ending (fig. 10),
- ended with an olive and curved (fig. 11),
- ended with a flat –cut aperture,
- with a spiral ending,
- with a conical ending.



Fig. 10. Urethral catheter with a semi-circular ending

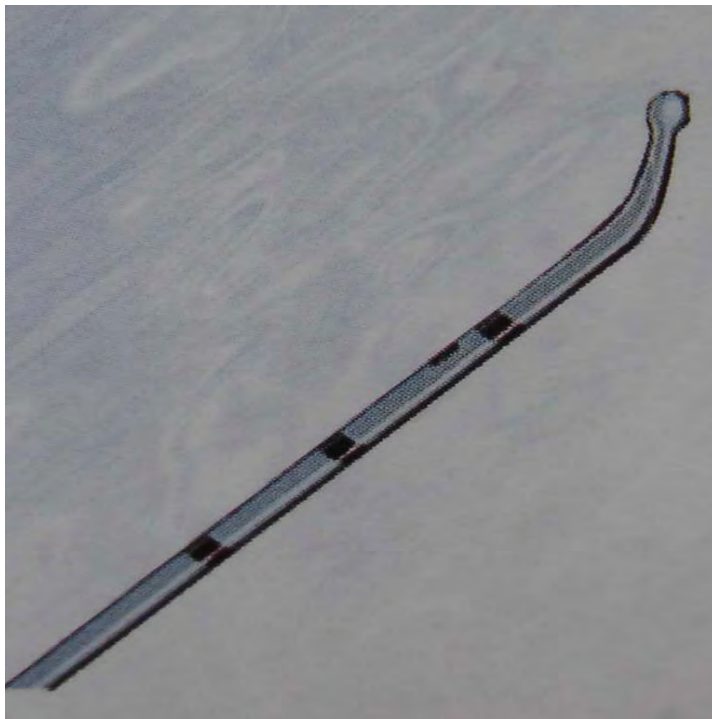


Fig. 11. Urethral catheter ended with an olive and a curve that facilitates the introduction into the aperture of the bladder ureteral orifice

These catheters are used to drain the urine from the urinary tract or renal pelvis outside the urinary tract. They are also used in diagnostic examinations (pyelography).

Aiding tools in the treatment and diagnosis of the diseases of the urinary tract and renal pelvises:

Zeiss' loop,

Dormi catheter,

a brush for the collection of material for cytological examination

Zeiss' loop and Dormi catheter are useful in removing small stones from the urinary tract (fig. 12).

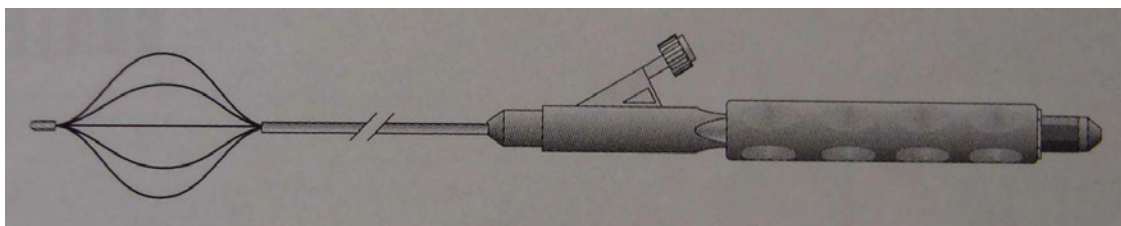


Fig. 12. Dormi catheter with a characteristic basket for capturing and removing deposits from the urinary tract

Using these instruments we can remove not only primary stones but also the ones that originate and remain in the urinary tract after lithotripsy with new methods of treatment such as Extracorporeal Shock Wave Lithotripsy (ESWL) or Percutaneous Nephrolithotripsy (PCNL).

Catheters with an ability of self-maintenance in the urinary tract: these are catheters with one or two curved endings in the shape of a spiral or pig's tail. They are made of materials that allow straightening the catheter on the conducting instrument while it is being introduced into the urinary tract, and after the removal of the conducting instrument, the catheter regains its curved ending. This enables the catheter to remain safely in the renal pelvis, the urinary tract and the bladder, protecting it at the same time from changing its position or falling out of the urinary tract. There are two types of such catheters:

- catheters with two curved endings (fig. 13),
- catheters with one curved ending.



Fig. 13. Double-J catheter remaining in the urinary tract

This type of catheter is made of materials that allow maintaining it in the urinary tract from 3 to 12 months.

Gynecological examination

Gynecological examination, as any other medical examination, consists of taking the history of symptoms and signs and performing physical examination. Taking history is very much dependent on winning patient's trust in order to elicit frank, simple answers from her. It is often difficult since the matters in question may concern a very intimate sphere of patients' life, arousing their embarrassment and distress. It is essential for the doctor to approach his/her patient in a respectful, gentle, calm and sensible manner, to help her overcome her feelings of self-consciousness and discomfort. The doctor should always courteously greet a patient, introduce himself to her and ask her to take a seat, remembering that a properly taken history may be crucial for determination of the appropriate diagnostic procedures and correct diagnosis. Symptoms suggestive of pathology of the reproductive system are an indication for the gynecological examination. To screen prophylactically for cancerous changes in the reproductive organs, the gynecologist performs annually routine endoscopic and *per vaginam* examinations.

Taking history

The most common symptoms reported by patients are menstruation disturbances, abnormal bleeding from the genital organs, pains in the hypogastrium and abdomen, leukorrhoea, and self-detected masses in the abdominal cavity or breast. Older patients often complain of symptoms associated with menopause, which is related to declining activity of the ovary. The main causes of complaints in this period of life are disorders of the neuro-vegetative system. Younger patients often come to ask advice on the commencement of sexual activity and choice of a contraceptive. Another purpose of visits to the gynecologist is medical check-up for cervical and breast cancer. Cervical cancer accounts for 60% of all neoplasms of the reproductive organs. It can be detected at its early stage in erosions when effective treatment is still possible. Patients must be always strongly reminded to undergo regular prophylactic tests. In Poland about 4,000 cases of cervical cancer are diagnosed every year, with mortality rate reaching 2,000 (as in 1996), which makes cervical cancer the fourth most common cause of cancer-related deaths.

Physical examination

To start with, general appearance of a patient is considered: her behavior, movements, body build and body mass, facial expression, timbre of voice. The doctor asks the patient to strip from

the waist down and to take dorsal lithotomic position on the gynecological chair, the most suitable for examination. *Per vaginum* examination enables the doctor to gather information that is indispensable to determine the condition of the pelvis minor organs. To obtain additional information for establishing the diagnosis, *per rectum* examination can also be performed. Apart from genital assessment, woman's breasts should be examined, since they produce the same hormones as the uterus, oviducts and vagina, i.e. mainly estradiol, progesterone, prolactin, and oxytocin.

Inspection involves examination of the labia. Small, hypoplastic labia minora, small clitoris, and sparse pubic hair suggest hypoestrogenism. Hypertrophy of the labia minora and clitoris, labial hyperpigmentation and male-like distribution of hair indicates hyperandrogenism and requires hormonal tests. By inspecting the vestibule of the vagina the doctor assesses the type and condition of the hymen. If a patient has not yet had a sexual intercourse and there is a risk of damage to the hymen during examination, examination *per rectum* should be performed. At the base of the labia, on both sides of the inlet to vagina, there are orifices of Bartholini's glands, the secretions of which moisten the vestibule. Inflammatory conditions can result in formation of big, painful abscesses of these glands. Herpes or tiny pointed condyloma in the labial region can point to a viral infection. Lesions in the form of ulceration, exophytic vegetations and depigmentation are suggestive of neoplastic changes and should be thoroughly diagnosed.

Viewing the vagina is a further step in examining a patient. It is performed with the use of a sterile two-arm speculum, or single Cusco type speculum, where the two arms are joined with a hinge. After selecting a matching size speculum, the examiner parts the labia with his thumb and index finger, and inserts the speculum into the vagina. Using the two-arm speculum, first the rear arm is introduced. The arms should at the beginning be inserted vertically and in the course of or at the end of insertion turned horizontal. It is worth remembering that prior to insertion the speculum should be warmed and wetted, e.g. under running water, to reduce the patient's discomfort or pain and to relax the perineal muscles, thus facilitating the examination. On obtaining a clear view of the uterine cervix in the vaginal section, the shape, size and appearance of the external os of the cervical canal should be assessed. It must be remembered that cervical cancer develops most often on the border of the stratified squamous non-keratinized epithelium covering the cervical disc and the glandular cylindrical epithelium covering the cervical canal. The cervical mucosa does not undergo the process of exfoliation, but in the course of an ovulation cycle some changes occur in the structure of the secreted mucous. Estrogens reduce density and change mucous reaction to more alkaline milieu, which facilitates passage of sperm.

At ovulation stage, the cervical canal os is parted; the mucous becomes the least dense, tensile, forming 8-12 cm long fibrils. A smear of an ovulatory mucous drop crystallizes into a fern leaf shape. When the ovulation is over progesterone appears and the mucous becomes dense and incapable of crystallizing. In case of anovulatory cycles with no progesterone activity, the so-called relative state of hyperestrogenism results in continuation of cervical mucous crystallization during the 2nd half of cycle.

A normal cervical disc is smooth and shiny, pale-pink in color. In pathological conditions the cylindrical epithelium of the cervical canal may migrate onto the disc giving the picture of so-called glandular erosion. Infiltration of the squamous epithelium deeper into the cervical canal can also occur. In both cases the border between the epithelia shifts in relation to the level of the cervical external os. Obstruction of the ducts of cylindrical epithelium glands leads to the formation of retention cysts, the so-called Nabothian follicles, which are regarded as the evidence of an erosion spontaneous healing. Erosion may also be the result of inflammatory or postpartum lesions. Erosion does not tend to produce symptoms, or may be clinically manifested by contact bleeding or discharge. It is called a precancerous condition since it may develop into cervical cancer if untreated. Complete diagnostics of erosion involves viewing the vagina and performing cytological, microbiological and histopathological examinations of biopsy specimens obtained from the pathological lesion.

While viewing, **diagnostic smears can be collected**, such as:

1. **Microbiological smear**, or vaginal 'cleanliness' test. The material is collected from the vaginal posterior fornix.
2. **Cytological smear**: using a speculum, the examiner locates the uterine cervix and swabs the mucous plug from the external os of the uterus. Then he collects material from the canal and cervical disc with a spatula or cytobrush. This test is done as prophylaxis to screen for malignancy in women of 25 to 65 years of age. It should be repeated regularly once sexual activity starts.
3. **Cytohormonal smear**: performed to assess hormonal activity of the ovaries. Cell material is collected from the vaginal lateral fornix. At least 4 or 5 preparations are analyzed, at the follicular, periovulatory, early luteal and late luteal phases.
4. **Taking biopsy specimens for histopathological examination**: cervical cancer is often detected within the borders of erosions when still at early stage and when effective treatment is still possible. Colposcopy is used to perform target tissue biopsy.

5. **Vaginal discharge macroscopic assessment:** this is also an exploratory examination used to find the pathogen responsible for an inflammatory condition of the vagina. Normal discharge is liquid, moderately profuse, odorless, milk-white in colour, which is due to the presence of lactic acid bacteria (Doderlain's bacilli). In pathological conditions, presence of discharge (leukorrhoea) that is profuse, purulent, dense, and yellowish indicates bacterial infection. White, lumpy and caseous discharge, accompanied by pruritus, is characteristic of fungal infection. Frothy, yellow-greenish discharge of unpleasant odour suggests trichomonal infection. Discharge from the urethra is also assessed – purulent discharge may be suggestive of gonorrhoeal infection.

On completion of viewing the vagina, while removing the speculum, examination of the vaginal walls should be done for pathological changes such as i.e. papillomas or carcinomas. If the vaginal walls are markedly lowered, anterior vaginal wall elevated by the urinary bladder or posterior vaginal wall raised by the rectal ampulla can be visible in the vulvar fissure. To check for urinary stress incontinence, the patient should be asked to cough.

On **palpation**, the shape of the abdominal vault, abdominal wall tonus, and tenderness to palpation should be assessed and any symptoms of peritonitis looked out for. We should also check for pathological masses suggestive of tumors of the uterus, ovary or the intestine. Presence of ascites is the evidence of cancerous lesions or liver cirrhosis.

Examination *per vaginam* should be done after the patient has earlier emptied her bladder. Before inserting his one or two fingers into the vagina, the examiner must put on a sterile surgical glove. While introducing the middle finger, we press the posterior wall of the vagina to make room for the index finger. Examination of the female reproductive organs usually requires both hands; hence it is called a **bimanual** or combined examination. The examiner endeavors to grasp the uterus with the fingers of the 'internal' hand – its fingers inside the vagina, lifting the uterus upwards, and 'external' hand – its fingers over the pubis, pressing the abdominal wall. During this examination, position of the corpus of the uterus (ante- or retroflexion), its size, shape, compactness, mobility and tenderness are inspected. Examination of the retroflexed uterus is considerably more difficult, and sometimes, additional examination per rectum may be advisable. During the examination, the patient should be relaxed, her arms along the body.

The corpus of the uterus is the size of a small pear, about 5-6 cm long, 4-5 cm wide, and 3-3.5 cm thick. The uterus is a hormone-sensitive organ: a small, hypoplastic uterus indicates a possible hypoestrogenism, while an enlarged uterus is associated with an increased estradiol level, due for example to early pregnancy. The normal tonus of the uterus corresponds to that of

skeletal muscle, whereas gestational uterus is softer. Irregularities in the outline of the uterine corpus may be associated with the presence of benign tumors, the so-called myomas. Suspension of the uterus by means of peritoneal ligaments and fibrous bands determines its mobility. Pain on shifting the uterus during the examination will indicate inflammation of adnexa or parametrium, or endometriosis. Fallopian tubes are normally long and thin, and not palpable on gynecological examination. If inflamed, however, they can be palpated, and strong pain can be experienced. Exudate in a fallopian tube is associated with the presence of a soft tumor such as hydro- or pyosalpinx. The ovaries are elliptic in shape, 30 mm long, 20 mm wide, compact, a little tender on pressure. In obese women, the ovaries may not be palpable. Women of androgenic hormonal build, on the other hand, often have enlarged ovaries, about 40mm x 30mm, which is the result of subcapsularly located follicles and hypertrophy of ovarian medulla. To palpate the adnexa, fingers of the 'internal' hand should be inserted to the lateral fornix of the vagina, pressing towards the parametrium and exerting simultaneous pressure to the abdominal wall by the fingers of the 'external' hand.

It is worth emphasizing that estradiol has a stimulating effect on the uterus, inducing growth of its muscular layer, increasing contractility of myocytes, and proliferation of endometrium cells. In the breast, estradiol leads to increased growth of ductules. Progesterone acts opposite to estradiol, decreasing contractility of myocytes, inhibiting proliferation and secretory transformation of the endometrium. In the breast, it causes growth of lobules and glandular vesicles. A long-term absence of such feedback estradiol-progesterone mechanism due to, for example continuing anovulatory cycles, may result in many abnormalities of structure and function of the reproductive organs. The hormone, which often disturbs the estrogen-progesterone balance, is prolactin. There is a simple sign evidencing excessive secretion of prolactin – the nipple of a woman who is not in lactation period will produce milk on squeezing. This only proves that examination of breasts should always be a part of gynecological examination of a woman.

Ophthalmoscopy

Direct ophthalmoscopy is the most common method of examining the eye fundus. It provides a 15x magnified upright image of the retina.

Ophthalmoscopy is much easier through a dilated pupil. Tropicamide 1% drops (0,5% for children) are recommended. The pupil mydriasis starts 10 to 20 minutes after installation and lasts for 6-8 hours.

There is a small risk of angle closure glaucoma caused by mydriasis in eyes with shallow anterior chambers, particularly in elderly patients.

Examination sequence for ophthalmoscopy

- Use a dark room.
- Ask the patient to look at a distant object and to breathe normally.
- To examine the right eye, hold the ophthalmoscope in the right hand (hold it in the left hand while examining the left eye).
- Use your right eye to examine the patient's right eye and use your left eye to examine the patient's left eye.
- Switch on the instrument and direct it at the pupil, angling it slightly towards the nose.
- Demonstrate the red reflex.
- Keeping the beam pointing in the same, slightly nasal direction and the red reflex in view, move the ophthalmoscope more closely to the patient's eye, stopping just close to the lashes.
- The optic nerve (disc) should now be in the field of view.
- Examine the fundus systematically, directing the ophthalmoscope adequately.
- Finally examine the macula. It is difficult to see it through a small pupil. Use a narrow beam and ask the patient to look straight at the light.

The normal fundus

Retina.

The color of the retina varies considerably according to skin and choroidal pigmentation, from reddish black in those with black skin to pale pink in the Albinos.

Optic disc.

The optic disc is pink with a slight temporal pallor. The margin is well demarcated except for the nasal side. The optic cup is paler than the rest of the disc and varies in depth and size but its diameter should not exceed 50% of the whole disc diameter.

Macula.

The normal macula lies temporally to the disc within the vascular arcades; it is darker than the rest of the retina and has a shiny central (foveal) reflex.

Blood vessels.

The bifurcation(s) of the central artery and vein are visible at the disc. Transmitted physiological pulsations of veins may be present. Arterial pulsation is abnormal. The upper and lower branches of the artery divide into nasal and temporal arteries. These arteries are smaller in diameter than the veins and are brighter red.

PHYSICAL DIAGNOSIS IN OTORHINOLARYNGOLOGY

The nose and nasal sinuses

Taking history

Labored respiration can be the result of the nasal septum deviation, hypertrophy of nasal conchae or vasomotor changes (allergic). Another reason for labored nasal respiration may be edema in the course of flu-like diseases in spring and autumn or allergic swelling of the mucous membrane in spring, when grass and trees blossom. Sinusitis, nasal polyps or malignant neoplasms may also cause it. Headaches that are caused by sinusitis begin in early morning hours and are associated with mucopurulent, often fetid secretion. Localization of the pain is varied; the most common being in medial corners of the orbits.

External nose inspection

On inspection, attention should be paid to the shape of the nose, its shifting, intussusception, swelling of the orbits and livedo, osseous or cartilaginous septal defect, congestion, dermatitis (atrial nasal furuncle), tenderness on palpation of flaccid parts and surrounding tissues.

Tentative examination of nose patency

In everyday ambulatory examination, an estimation of nose patency is cursory and limited to quantification of freely expired air stream force when it reaches doctor's hand. The air is expired with one nasal passage closed. After cleaning the nose the patient is asked to breath freely and after applying pressure on one side of the nasal ala, strength of the exhaled air stream is assessed on a dorsal side of a hand.

Anterior rhinoscopy

Rhinoscopy is performed with a headlight and a nasal endoscope; the patient is sitting. After introducing light into the nasal atrium, arms of a closed rhinoscope are inserted into one of the nasal passages. A rhinoscope is always kept in the left hand. Its handles are held in the

hand and the forefinger is free to touch the tip of the nose. Clamping the handles makes the nasal atrium open. Touching mucous membrane, especially nasal septum should be avoided as it is painful and may cause bleeding. Doctor's right hand should rest on patient's forehead and control head position. In lighted passage (e.g. on the left side) shape of the septum should be examined. Rarely is it straight and may have various shapes. Its lower part may be rich in fine vessels. It is called Liettl's or Kiesselbach's plexus. It often bleeds. There are three nasal conchae on the lateral wall: superior, middle and inferior. They appear as rounded thickenings of different size and mucous-like color.

Paranasal sinuses can only be examined radiologically or by diagnostic puncture, which refers only to the maxillary sinuses. Morning headaches and tenderness around medial corners of the orbits and cheeks just under the shaft of the zygomatic bone may suggest maxillar, ethmoid or frontal sinusitis but the correct diagnosis is often difficult.

Posterior rhinoscopy

Mucous membrane of the oropharynx should be anaesthetized before the examination. The epiphysis of the tongue is gently pressed with a spatule held in the left hand. A small laryngeal mirror, which is held in the right hand, should be previously warmed. A patient is asked to breathe in as if sniffing. Then the mirror should be placed behind tensed soft palate so that its lighted surface is at the angle of 45°. The mirror is turned with its reflective surface up and a ray from a headlight reflexes to light up the ceiling of the oral cavity, which is properly called the oropharynx. A view in the mirror shows the postero-medial part of the nasal septum and oval posterior edges of the conchae - laterally on both sides.

A different way to examine the nasopharynx is palpation. Patient's head is stabilized in doctor's left hand (doctor is standing next to patient, on his right). With the forefinger of the left hand, a fold of buccal tissues is placed between the teeth of maxilla and mandible from the outside. It protects the examiner from being instinctively hurt, bitten.

Doctor inserts the forefinger of the right hand into the oral cavity and then into the nasopharynx (behind the soft palate) and palpates for any pathological structures.

The oral cavity and the pharynx

Taking history

As usual, age and sex should be included. Scratching, foreign body feeling or sore throat may result from hypertrophic or atrophic chronic pharyngitis exacerbation. Halitosis may be the result of caries or alimentary diseases (e.g. oesophageal diverticles). Bleeding from the oral cavity (especially in mornings) may be provoked by overzealous brushing (alveolar process microinjuries). Frequent complaints of sore throat need differentiation with acute tonsillitis (local distress) and pharyngitis (systemic infection with strong pain, high temperature, malaise and distant complications). Pain on swallowing, as well as voice weakness, timbre changes or hoarseness, require assessing trachea condition, especially if pain radiates to the ears (neoplasms).

Inspection and palpation of the oral cavity and the pharynx

On the oral cavity and pharynx examination, the left hand is placed on patient's forehead, while the right hand holds a spatula. The patient is asked to open the mouth. After illuminating, the tongue (mobility, fur presence), the orifices of submandibular glands (frenulum of the tongue) and condition of the dentition are examined.

Next, labia and buccae are drawn apart to examine the vestibule of the oral cavity, particularly the area of last premolar teeth, where the orifices of the parotid glands are localized. Examination of the soft palate, tonsils and the posterior wall of the pharynx is performed after pressing the tongue (without hesitation) near its epiphysis but not too deep (vomiting reflex) with a spatula. On inspection of the soft palate, attention is paid to symmetry of its tension and to palatine tonsils that are localized between palatine arches. They may be hypertrophic or hidden in the arches.

The posterior wall of the pharynx shows solitary or aggregated lymph follicles that form the lateral tracts. They are often observed as small, bright red nodules, which suggests chronic, exacerbated hypertrophic inflammation. Smooth, dry and lucid mucous membrane is observed in chronic atrophic inflammation. On palpation, lymphoid nodes of the submandibular area are examined. Sometimes (after putting on a glove), the bottom of the oral cavity, particularly the

orifices of the submandibular gland ducts can be palpated.

The larynx

Taking history

On obtaining the history, endured infectious diseases such as tuberculosis and diphtheria should be enquired about. If the patient complains of frequent colds with hoarseness, precise frequency should be established as well as the information whether these are accompanied with cough, pain while swallowing, scratching or tickling sensations just under the larynx or earache should be obtained. Symptoms that have been described may suggest chronic, aggravating laryngitis or tracheitis but may also suggest the beginning of a serious neoplastic disease. Patient's consumption of high percentage alcohol, smoking intensity and dietary habits like eating hot, spicy or cold dishes have to be assessed as well.

In case of dyspnoea, it is necessary to establish its etiology. Acute tracheal dyspnoea is very typical as it is an inspiratory dyspnoea with stridor.

Neck palpation

On palpation a lateral mobility range of the trachea, tenderness (inflammation of the cartilaginous framework) and localized pain on both sides of the hyoid bone (inflammation of the superior laryngeal nerve) are examined. Cervical nodes along the sternocleidomastoid muscle as well as submandibular and supraclavicular nodes also need palpation. Special attention should be paid to the nodes of the angle of the mandible, because metastases of nasopharyngeal neoplasms are formed there frequently, being the only symptom of the disease.

Indirect laryngoscopy

The technique of the indirect laryngoscopy is as follows: the patient sits in front of the doctor and, after choosing a proper laryngeal mirror, the doctor warms it over a flame of a spirit lamp or dips it in hot water for a few seconds and checks its temperature against his hand. Then he asks the patient to stick the tongue out and seizes it with his left hand, using gauze. Warmed mirror (to avoid fog) is introduced into the middle pharynx and lifts the uvula

and the soft palate. A mirror should be advanced at the angle of about 45° and, after the area has been illuminated using a headlight, it should show the view of the larynx. The foreground shows a semi lunar edge of the epiglottis passing into symmetric aryepiglottic folds, which are connected with two cherry stone-sized prominences - the arytenoid cartilages. Laterally on both sides, there are big hollows called the piriform recesses. Anteriorly from the arytenoid cartilages, two white-silvery strips pass, which (on breathing) form a triangle with the cartilages that is called the glottic fissure. These are vocal folds, called also vocal cords (chorda vocalis). These are connected to the edges of the thyroid cartilage with spurious folds, which are visible as a filling of the space between the cords and lateral surface of the larynx. It is possible to observe their constriction during phonation and relaxation while breathing.

The ear

Taking history

The type of hearing defect should draw our attention; how the speech is heard, interpreted and perceived (wrong comprehension and poor hearing of informative sounds, e.g. ring in receiving defects). In transmission defects (inflammations, otosclerosis) phone calls are heard correctly due to the bone transmission. If hearing disturbance is accompanied by murmurs, whistles or squeals it may suggest receiving defects (acoustic nerve) or eustachitis. Basic data should be noted in the history: patient's age (natural ageing of the hearing organ), sex (in women, otosclerosis affects hearing without pain and secretion) and profession (working in noisy environment- acute and chronic acoustic trauma).

Ascertain if any vertigo occurs. If it happens while changing position from the horizontal to vertical, it may be an orthostatic dysfunction of circulation and not the typical dizziness.

On taking history one should establish:

- giddiness - is a kind of spinning around (body, objects) or hesitated walk;
- circumstances, in which vertigo occurred (suddenly, gradually, after an injury, during infection, after poisoning, after psychic trauma);
- if it is related with hearing disturbances;
- what are the co-occurring symptoms e.g. unconsciousness;
- how the disease evolved from the onset to the present – if dizziness is recurrent;
- if it aggravates or diminishes;

- if it is periodical.

Inspection and palpation of the external ear

The shape of the auricle, width of the external auditory canal, skin color, inflammation, swelling, eczema, congestion, swelling and pain on palpation near the mastoid process, pain on pressing the tragus or the postero-inferior section of the acoustic duct and pain on percussion around the mastoid process are the matters of concern.

Ear endoscopy – otoscopy

Tortuosity of the external acoustic duct demands funnel-shaped auriscope. Its size is selected according to the anatomical condition of the ear canal. After introducing light with a headlight (e.g. during the left ear examination) the auricle is pulled back and in an upward direction by the left hand. The otoscope, which is held between the thumb and the forefinger of the right hand, is inserted into the auditory canal with a rotating movement.

An auriscope should be inserted extremely gently, up to the cartilaginous part of the canal only, because the bony part is directly covered with the skin and its triggering could be terribly painful for the patient. The skin of the canal can be inspected after auriscope has been inserted. Then, the tympanic membrane is examined. Normally, it is of pearl-grey color. Superiorly and medially, there is a small bulge protruding to the canal. It is the short hammer processus. There is also a place of hammer's attachment that is ended with a hollow visible here; it is called the umbilicus. It runs obliquely from above to the bottom. A reflection forms light streak heading forward. In adults, white spots of calcium plaques are noticed frequently. A close examination of the tympanic membrane needs experience.

Significant amounts of cerumen may accumulate, which makes inspection of the membrane difficult or impossible. Mechanical removal with a hook or ear lavage is recommended.

Assessment of student's practical clinical skills

Objective Structured Clinical Exam

One of the methods of checking and evaluating clinical skills is an Objective Structured Clinical Exam (OSCE). This kind of test of clinical skill performance is widely applied in medical departments of many leading medical universities in North America and Western Europe. An OSCE is considered the best way to evaluate practical clinical skills and may be efficiently applied in pre- and postgraduate medical teaching. Basic structure of an OSCE is not dependent on specific skills tested. The exam includes several stations (usually 10 to 15) involving performance of different tasks. Each station corresponds to one practical task or clinical problem, which should be solved in a limited time period (3 to 6 minutes). The particular tasks are constructed to resemble clinical situations that are encountered in real settings. Therefore, according to the kind of task the student can meet at the consecutive stations a healthy volunteer, a standardized or real patient as well as a phantom of the whole human body or its part. While passing through each station, the examined person is observed by the examiner and is estimated using previously prepared and precisely defined criteria of assessment. In this way each student has the same set of tasks to solve within the same time period and is estimated according to the same criteria. In comparison with traditional practical examination where students have different patients assigned to discuss in a different time period and are estimated by examiners who usually apply different methods of evaluation, an unquestionable advantage of OSCE is that it provides a uniform, objective method of assessing clinical skill performance by students. The analysis of obtained results can also be used to evaluate the quality of teaching.

Preparation of OSCE is not an easy task and requires a large commitment of the whole teaching team. While planning OSCE it is necessary to solve a variety of problems, which are introduced below. These are as follows:

- selecting the clinical skills, which are to be checked
- defining the number of stations and subordinating suitable tasks to them
- providing each station with short, unambiguous instructions that would define the task
- establishing the method of assessment
- preparing the place for the examination - at least a few joint rooms will be necessary

- selecting the staff necessary for examination execution: examiners, volunteers, patients, persons responsible for regulating the students' passage through the stations (supervising the order and time of executing tasks, making sure that there would be only one examined student at one station)
- training the staff
- settling the date of the examination (it may be troublesome since several rooms are required at the same time)
- analyzing the results

A proper training of all persons that are engaged in preparation and execution of OSCE seems essential. It concerns both the examiners and patients or healthy volunteers, who play the suitable roles described in the script of tasks that are subordinated to the particular stations. Standardized patients must present with the same symptoms and complaints that are associated with their diseases each time they are examined. Two instructions have been introduced below. The first instruction has been designed for a healthy volunteer, who is supposed to play the role of a patient with pneumonia. The second one, which is addressed to an examiner, includes the criteria of evaluating student's performance of taking history from a patient with pneumonia, who has visited his doctor because of cough, shortness of breath and fever.

Station No. 1 – history taking (pneumonia)

Instruction No.1 (script for a standardized patient)

You are a 66-year old man, a former electric locomotive engine - driver, at present - retired, healthy so far. You have smoked about 10 cigarettes daily for 40 years. Three days ago you went fishing. It was a cold, rainy and windy day. You soaked and froze. The day following your return home cough appeared, initially without any sputum, and then you produced yellow-green sputum on coughing (without the presence of blood). Chills occurred in the evening, the body temperature was 39.4° C. The feeling of shortness of breath as well as chest pain, which increased on deep breathing and coughing, occurred in the right half of the chest. The body temperature that was measured this morning was 38.6° C. You feel weak, produce green sputum with no bloody admixture, feel piercing pain in the right half of the chest that is more intense on breathing, you cannot walk. You have not taken any medicines except for 2 tablets of paracetamol in the evening. The standardized patient has to know this script very well and should give the same answers to all the examined students.

Instruction No.2 – Evaluating the student

Station No 1. – history taking (pneumonia)

Instruction for a student: Take a short medical history from the patient admitted to hospital due to cough, fever, weakness and discomfort in right half of chest. Based on the information, present the most likely, working diagnosis. You have 6 minutes to complete the task.

Rating criteria	points
Did a student introduce himself and greet the patient?	1
Did he inquire on:	
- duration of symptoms	1
- circumstances of their appearance	1
- cough	1
- production and colour of sputum	1
- evidence of blood in sputum	1
- toleration of exercise	1
- dyspnea	1
- fever	1
- pain	1
- chills	1
- smoking habit	1
- past medication	1
- occupation	2
Initial diagnosis	3
Maximum rating	19

Examiner should remain close to the standardized patient and the examined student so that he could precisely analyze their dialogue and execute his opinion according to the above-mentioned criteria. In the Practical Clinical Teaching Center, several variants of OSCE have been worked out and used as a method of estimation of practical clinical skill performance after completion of the course. The list of tasks concerning the two exemplary examinations is presented below.

OSCE (first version)

Station	Task	Rating method
1	Taking medical history of the current disease (pneumonia, standardized patient)	observation
2	Measurement of blood pressure and interpretation (healthy volunteer)	observation
3	Tentative percussion and auscultation of the lungs (healthy volunteer)	observation
4	Palpation of the liver and the spleen (healthy volunteer)	observation
5	Recording an ECG (healthy volunteer)	observation and interpretation of the record
6	CPR (phantom)	evaluation of printout from phantom
7	Investigation of pulse on large vessels (healthy volunteer)	observation
8	Principles of vein puncture (written answer in several points)	written answer checking
9	The arrangement of unconscious subject in a settled position (healthy volunteer)	observation
10	Calculation of heart rate based on ECG record (3 ECG records, written answer)	checking of calculations
11	Determining heart borders and location of the apex beat (healthy volunteer)	observation
12	Investigation of respiratory action and determination of lower borders of lungs (healthy volunteer)	observation
13	Cleaning the wound and applying a dressing (phantom)	observation

OSCE (second version)

Station	Task	Rating method
1	Investigation of breasts (phantom)	observation
2	How to prepare a patient for funduscopy (written answer, points)	written answer checking
3	Performing catheterization of the urinary bladder (phantom)	observation
4	Per rectum examination (phantom)	observation
5	Description of breast tumor – shape, dimensions, location (written answer based on palpation of breast; phantom)	written answer checking
6	History taking from the sick child's mother	observation
7	Suturing a wound (upper limb, phantom)	observation
8	Calculation of duration time of PQ interval and QRS complex based on ECG record	written answer checking
9	Rinsing the ear canal	observation
10	Applying compression dressing on a wounded upper limb (arterial hemorrhage, phantom)	observation
11	Beginning resuscitation (CPR, phantom)	observation
12	Auscultation of heart valves (healthy volunteer)	observation

Six minutes are provided to complete every task. Having completed the course in the Clinical Medicine Teaching Department, students should be able to perform all tasks described above. Passing score is 80%.

AUTHORS

1. Białasiewicz Piotr

Department of Clinical and Experimental Physiology

2. Ceranka Sławomir

Department of Invasive Cardiology, I Chair of Cardiology and Cardiac Surgery

3. Chiżyński Krzysztof

Department of Invasive Cardiology, I Chair of Cardiology and Cardiac Surgery

4. Cieśla Włodzimierz

Department of Clinical and Experimental Physiology

5. Glińska Joanna

Department of Nursing Skills and Theory

6. Grabska Izabela

Department of Clinical and Experimental Physiology

7. Grabski Władysław

Department of Essential Training in Clinical Diagnostics

8. Grymin Hanna

Department of Eye Disorders

9. Karasek Michał

Department of Neuroendocrinology

10. Kasielski Marek

Department of Essential Training in Clinical Diagnostics

11. Kawiński Janusz

Department of Cardiology, I Chair of Cardiology and Cardiac Surgery

12. Kolasiński Paweł

Department of Anesthesiology and Intensive Therapy

13. Kuzański R. Wojciech

Department of Surgery and Pediatric Oncology

14. Latkowski Bożydar

Department of Family and Social Medicine

15. Morawski Maciej

Department of Anesthesiology and Intensive Therapy

16. Niebudek-Bogusz Ewa

Institute of Occupational Medicine

17. Nowak Dariusz

Department of Clinical and Experimental Physiology

18. Pietras Tadeusz

Department of Pulmonology and Allergology

19. Różański Waldemar

Department of Urology and Urological Rehabilitation

20. Ruxer Jan

Department of Invasive Cardiology

21. Saryusz-Wolska Małgorzata

Department of Diabetology

22. Wesolek-Czernik Agata

Department of Eye Disorders